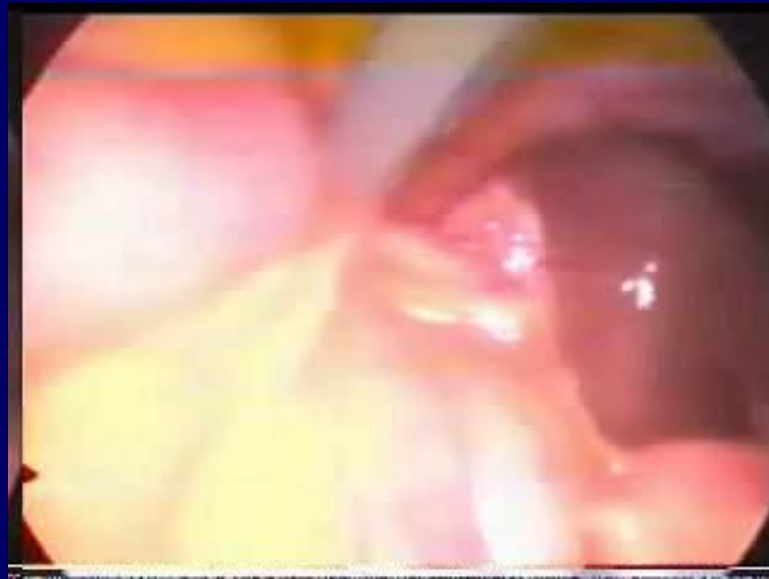



Laparoscopic Biliary Bypass For Distal Common Bile Duct Obstructions

Poschong Suesat , MD

Indications for Bypass of the Extrahepatic Biliary Tract

Benign

Multiple Stones

Intrahepatic Stones

Biliary Tree Packed with Stones

Stenosis of The Papilla of Vater

Malignant

Unresectable Tumor

The Surgical Biliary Bypass Procedures

Choledochoduodenostomy

Choledochojejunostomy

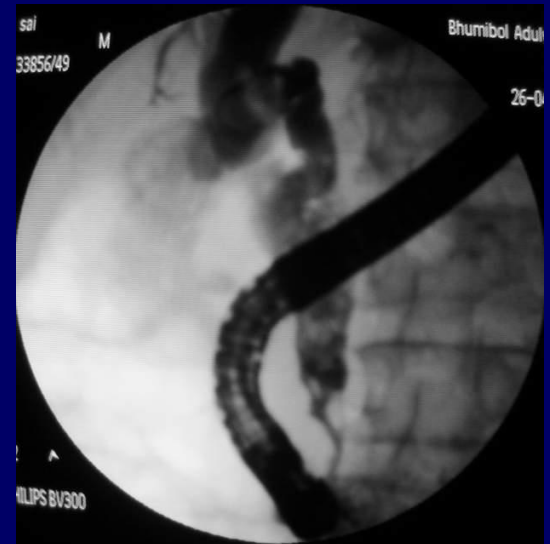
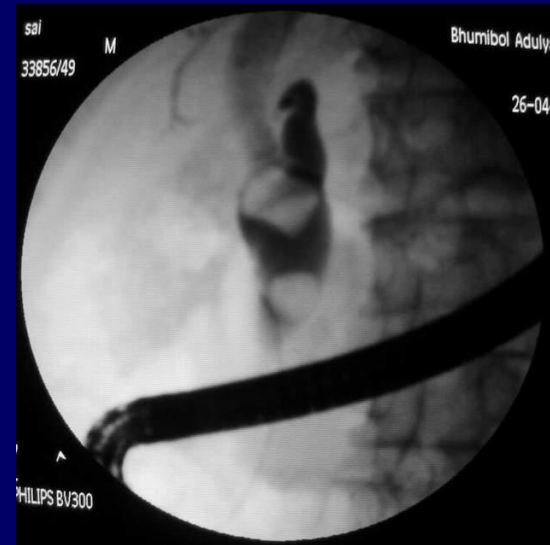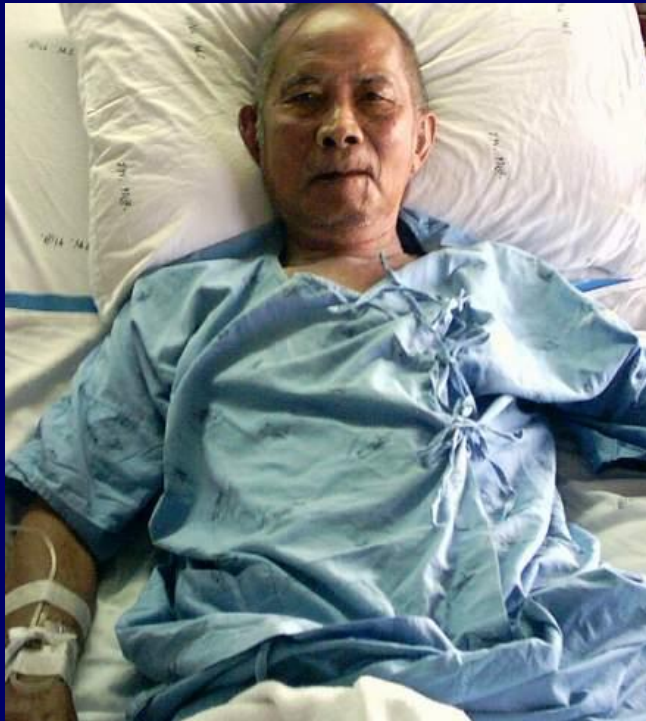Sphincteroplasty

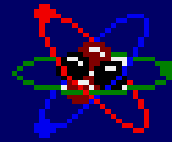
Cholecystojejunostomy

Hepaticodochojejunostomy

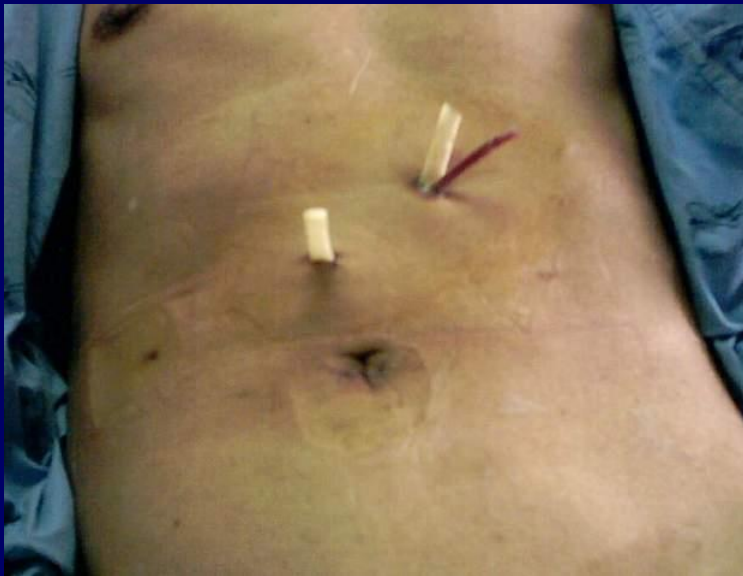
Case Report No 1

Laparoscopic Choledochoduodenostomy



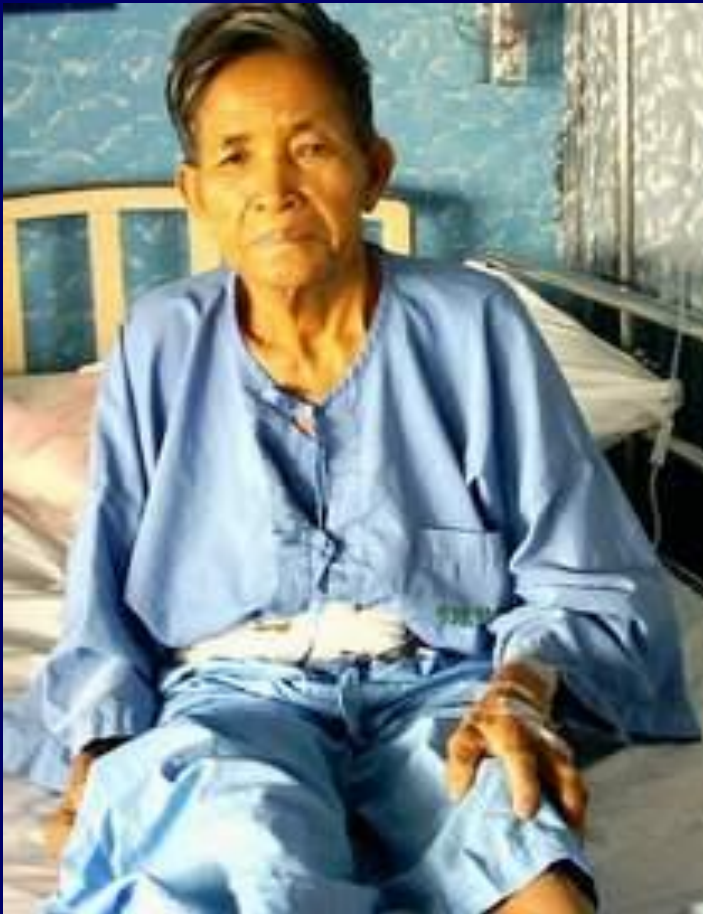


Laparoscopic Choledochoduodenostomy



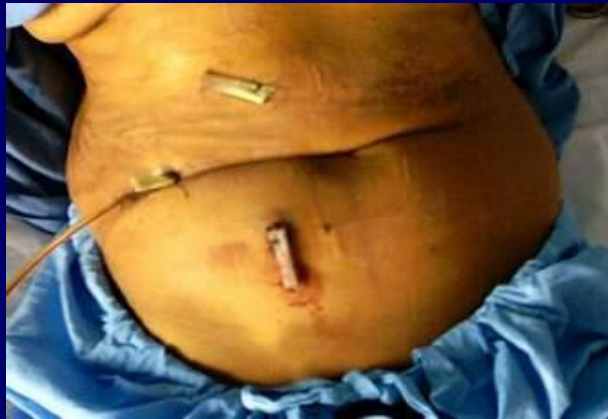
Case Report No 2

Laparoscopic Cholecystojejunostomy



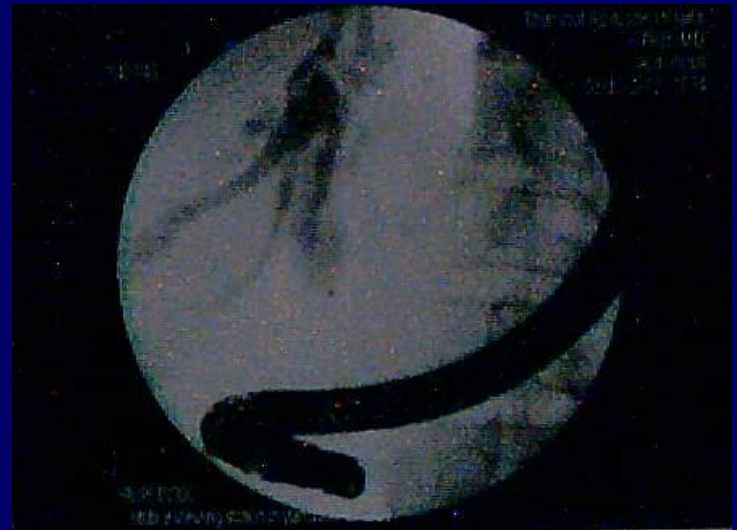
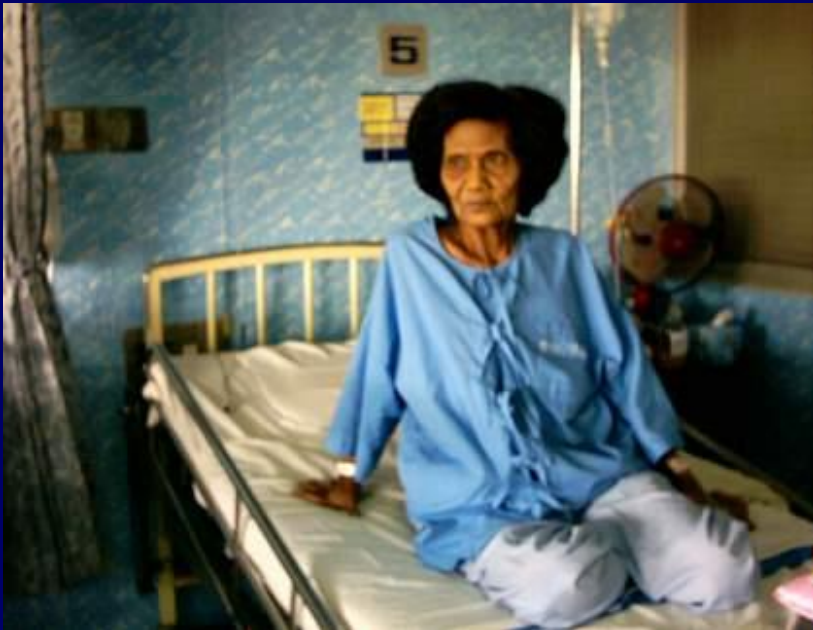
Laparoscopic Cholecystojejunostomy



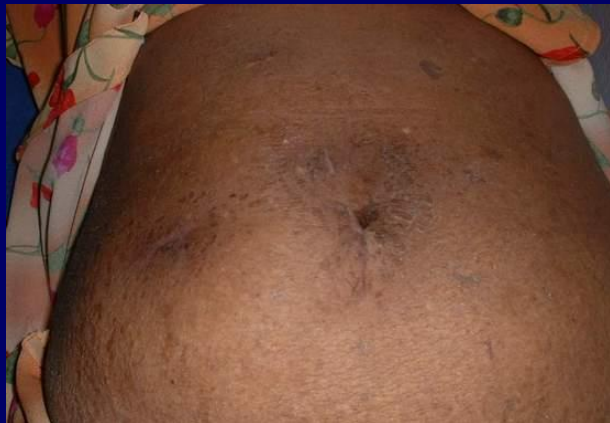
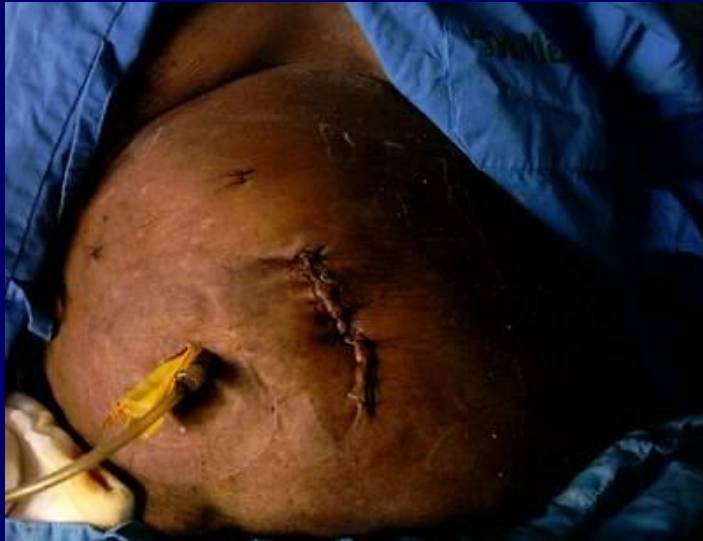Case Report No 3

Hand Assisted Laparoscopic Hepaticoduchojejunostomy





Hand Assisted Laparoscopic Hepaticoduchojejunostomy





**THE
END**

www.geocities.ws/thaisurgery