

## Giant Cardiac Myxoma : Report of 3 Cases

Apirak Chetpaophan, MD  
Chareonkiat Rergkliang, MD  
Vorawit Chittitavorn, MD  
Praserf Vasinanukorn, MD

Division of Cardiovascular and Thoracic Surgery, Department of Surgery, Faculty of Medicine,  
Prince of Songkhla University, Hatyai, Songkhla 90110, Thailand

---

### Abstract

**Background:** Primary cardiac tumors are rare and atrial myxoma is the most common cardiac tumor. With the advent of cardiopulmonary bypass surgical removal of the tumor becomes possible, particularly of the intracardiac tumor. This article reported the satisfactory outcome in surgical management by biatrial approach technique in 3 cases of giant left atrial myxoma that presented with clinical manifestation of congestive heart failure.

**Materials and Methods:** Retrospective data collection was carried out from medical records of all patients diagnosed with cardiac myxoma, who were admitted to Songkhlanakarind hospital, between August 2002 and July 2003. Surgical resection was performed as soon as possible by the biatrial approach technique.

**Results:** Three patients (2 Males, 1 Female), aged 42 to 50 years (mean, 44.6 years) presented with clinical manifestation of congestive heart failure were diagnosed by Echocardiography to have myxoma. All were in the left atrium (100%). The biatrial surgical approach was performed since it allowed total resection of the atrial myxoma along with its pedicle. There had been no postoperative morbidity and mortality.

**Conclusion:** Early surgical removal of cardiac myxoma should be performed as soon as possibility to prevent embolic complications. Our recent experience in 3 such cases with the biatrial approach, in allowing total resection of the myxoma, had low morbidity and mortality.

---

Primary tumors of the heart are rare. They were found in only 0.0017-0.19 per cent of unselected patients at autopsy.<sup>1,2</sup> Seventy-five percent of these tumors are benign. Half of them were myxoma.<sup>19</sup> Of the myxomas, 75 to 80 percent are located on the left side of the interatrial septum.<sup>10</sup> The advent of modern diagnostic procedures and cardiac operations have transformed primary cardiac neoplasm from a condition that is rarely diagnosed before autopsy to a potentially curable form of heart disease.<sup>3,17</sup> During the past year we experienced three cases of a giant left atrial myxoma which required an urgent operation. We reported the surgical management of patients with this rare disease.

### MATERIALS AND METHODS

#### Patient Data

Between August 2002 and July 2003, three consecutive patients were operated for left atrial myxoma at Songklanagarind Hospital (Table 1). Presenting symptoms were exertional dyspnea, orthopnea, generalized malaise, and palpitation. All patients had sinus rhythm. Mitral valve incompetence was present in two patients. Transthoracic and/or transesophageal echocardiography confirmed the diagnosis in all patients (Figure 1). One patient underwent cardiac catheterization and subsequent coronary angiography to exclude associated coronary

**Table 1** Patients' profile, diagnosis, operation, and pathology.

| Patient No. | Sex    | Age (years) | Diagnosis        | Operation                    | Tumor size (cm) |
|-------------|--------|-------------|------------------|------------------------------|-----------------|
| 1           | Male   | 42          | LA myxoma*       | Tumor removal                | 9×5×4           |
| 2           | Male   | 42          | LA myxoma & MR** | Tumor removal & MV repair*** | 6×5.5×5         |
| 3           | Female | 50          | LA myxoma & MR   | Tumor removal & MV repair    | 6.5×4.5×4       |

\*Left atrial myxoma, \*\*Left atrial myxoma and mitral regurgitation, \*\*\*Tumor removal and mitral valve repair (Mitral annuloplasty)

artery disease.

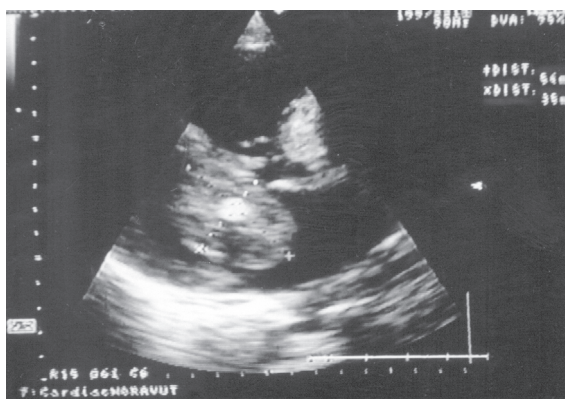
**Operative procedure**

All patients underwent median sternotomy. Cardiopulmonary bypass (CPB) was established via cannulas into the ascending aorta and both caval veins. Cardiopulmonary bypass with moderate systemic hypothermia (32°-34°C) and topical cooling was used for myxoma resection for all patients. Cold blood cardioplegic solution was delivered anterogradely through the aortic root. Additionally, topical saline

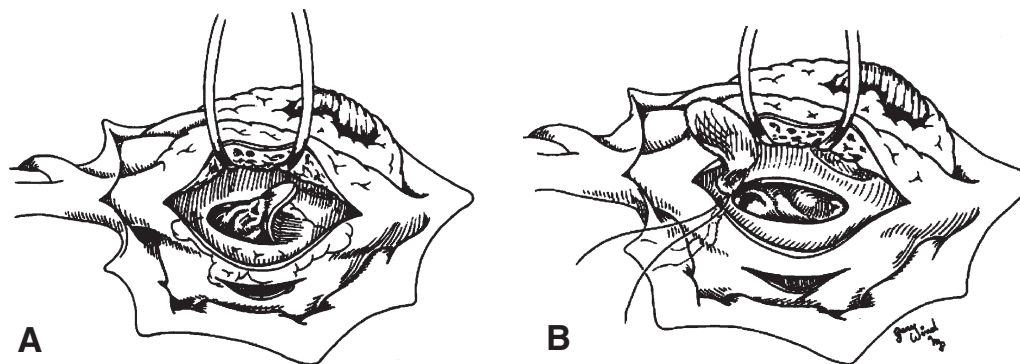
cooling was used. Care was taken not to manipulate the tumor before the aorta was cross-clamped. After cardiac arrest, a biatriotomy incision was performed (Figure 2). Exposure was considered to be excellent in all patients. All four cardiac chambers were thoroughly explored for additional myxomas. Left atrial myxomas were found in all patients. All tumours were removed en bloc with a full-thickness excision at the site of attachment (Figure 3). All interatrial septal defects were closed by an autologous pericardium or a synthetic patch.<sup>4</sup> Two patients had concomitant procedure done because of moderate to severe mitral regurgitation was also diagnosed. Therefore mitral valve repair was performed by plication at anterior commissure (Case No. 2) and the other (Case No. 3) was repaired by C-ring annuloplasty. Postoperative echocardiography revealed trivial to mild mitral regurgitation. Average total perfusion time was 71 ± 24 minutes, with an average total aortic crossclamp time of 51 ± 11 minutes.

**RESULTS**

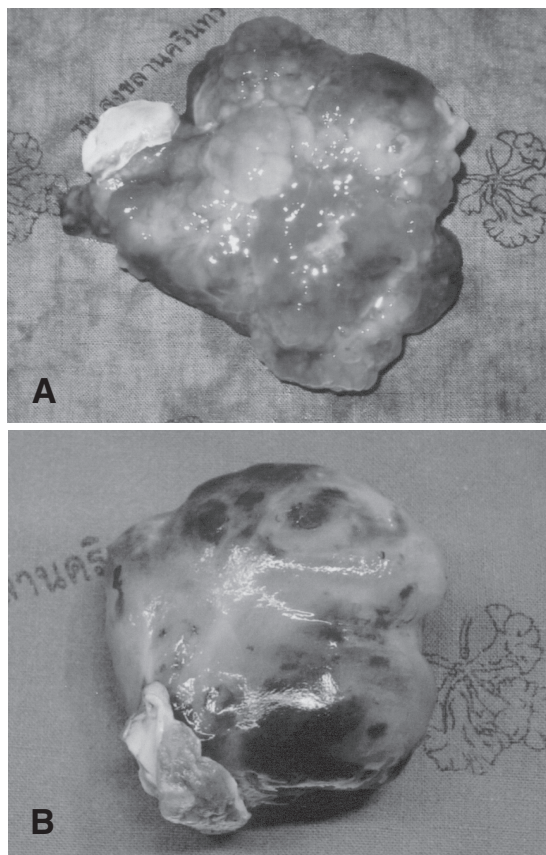
All patients were extubated from ventilatory support within 12 hours after operation. One patient had poor left ventricular function after operation and needed support by an inotropic drug for one week.



**Fig. 1** Echocardiogram showing a left atrial myxoma prolapsing across and obstructing the mitral valve. (Patient No. 1)



**Fig. 2** A The myxoma was resected en bloc through the biatriotomy approach with an adequate rim of interatrial tissue. B The atrial septal defect was closed either with a synthetic (Patient No. 1, 2) or a pericardial patch. (Patient No. 3)



**Fig. 3** Gross specimen of an atrial myxoma.  
 A The irregular, heterogenous, and polypoid nature of the tumor. (Patient No. 1)  
 B The gelatinous appearance of the tumor with hemorrhagic foci. (Patient No. 3)

The postoperative courses of other two patients were uneventful. None of the patients had a residual tumor and/or interatrial shunt demonstrable at postoperative echocardiography. All patients were well recovery and the following physical examinations were entirely normal one month later.

### DISCUSSION

Left atrial myxoma was first described in 1845.<sup>2</sup> The frequency of atrial myxoma is estimated between 0.5 and 1 per million of population per year.<sup>1,18</sup> In recent years, especially with the increase of echocardiographic screening, primary cardiac tumors have been detected earlier, hence the number of patients undergoing surgical removal of tumor has increased. All patients in this study were diagnosed by transthoracic echocardiography. Two-dimensional echocardiography can generally be used to determine the location,

size, shape, attachment, and mobility of cardiac myxoma.<sup>19</sup> It is noninvasive and does not pose the risk of tumor embolization. In our study, echocardiography was uniformly successful in diagnosing the tumor. Only one patient required coronary angiography that was the invasive catheterization procedure. In general, however, coronary arteriography is an undisputed investigation for preoperative evaluation of patients over 45 years of age, to rule out concomitant coronary artery disease.<sup>1</sup> Myxoma occurs with a family history in about 5% of cases.<sup>18</sup> In our report, none of the patients were familial type.

In our series, there are 3 main patterns of clinical presentation of cardiac myxomas, i.e. (i) hemodynamic consequences, (ii) embolisms, and (iii) constitutional manifestations, depending on tumor characteristics.<sup>19</sup> All patients had symptoms related to myxoma and related size of tumors. Although recent investigations have shown that are caused by interleukin-6 in plasma depending on the size of myxomas,<sup>4</sup> unknown factors may also affect this phenomenon. The most common symptoms included dyspnea on exertion, generalized malaise, and palpitation. After the diagnosis has been established, surgery should be performed promptly because of the possibility of embolic complications causing sudden death.<sup>3,4,16,17</sup>

The first surgical excision of primary cardiac tumor was performed in 1952 by Bahnson and Newman.<sup>3</sup> In 1954, Crafoord successfully removed an atrial myxoma by using cardiopulmonary bypass.<sup>8</sup> Nowadays the operation carries a very small risk. Cardiac myxomas arise mainly from the left atrial septum and three different surgical approaches are available.<sup>3,17</sup> These are: (i) a biatriotomy;<sup>4</sup> (ii) a right atriotomy; or (iii) a left atriotomy. Although the first two approaches have been performed by many surgeons, the most appropriate approach remains controversial. Some studies presented minimal access approach for resection of cardiac tumor and endoscopic-assisted superior septal approach that provided an excellent operative view and a safe tumor resection.<sup>5,6</sup> In this series, we used a biatrial approach for extensive resection of the giant left atrial myxomas because this allowed minimal manipulation of the large tumor and provided adequate exposure for complete resection. The biatrial approach is generally accepted technique that provides good exposure of the site of tumor attachment and adequate inspection of all four cardiac

chambers. When the root of the pedicle of tumor attachment and the full thickness of the adjacent interatrial septum are excised, repair of the resulting atrial septal defect requires a pericardial or synthetic patch. We performed one pericardial patch and two synthetic patches repair to prevent distortion of atrioventricular valve and achieve complete closure of the defect. For this reason, we do not advice direct-closure of defect. Mechanical damage to a heart valve or adhesion of the tumor to valve leaflets may call for valvular repair by annuloplasty or replacement with a prosthetic valve in some cases.

In the review of previous studies, we collected 42 cases of first recurrence from a total of 584 patients but very few cases (1.3%) of repeated recurrence.<sup>9-17</sup> Of the 42 cases of recurrence after removal of left atrial myxoma, 83 per cent of the second tumor occurred in the left atrium, 14 per cent in the right atrium, and 7 percent at other sites. The tumor recurred at, or close to, the original site in the left atrium in 85 per cent of cases. Reoperations were performed between 3 months and 14 years afterwards with an average of 3.9 years. The recurrent myxoma may be due to (i) inadequate resection, (ii) multicentricity, (iii) familial type, and (iv) metastatic recurrence.

Overall, despite the low rate of recurrence and metastasis, myxoma patients need to be followed up carefully. Postoperative echocardiography has been recommended to detect recurrent myxoma but the most appropriate interval is still controversial.<sup>3</sup> Because of the high incidence of recurrence tumor in first three years, we recommend annual echocardiograms for 5 years postoperatively, and thereafter if recurrence is clinically suspected.

### CONCLUSION

A high index of suspicion of cardiac myxoma is needed due to nonspecific clinical presentation. The diagnostic method of choice is echocardiography. Excision of myxoma should be performed as soon as possible because of the possibility of embolic complications. The long-term results were excellent for most of cases, but closed follow-up is needed due to the possibility of recurrence or malignant transformation.

### REFERENCES

1. Reynen K. Cardiac myxomas. *N Engl J Med* 1995; 333: 1610-7.
2. King TW. On simple vascular growths in the left auricle of the heart. *Lancet* 1845; 2: 428-9.
3. Centofanti P, Rosa ED, Deorsola L, Actis Dato GM, Patane F, Torre ML, et al. Primary cardiac tumors: early and late results of surgical treatment in 91 patients. *Ann Thorac Surg* 1999; 68: 1236-41.
4. Jones DR, Warden HE, Murray GF, Hill RC, Graeber GM, Cruzzavala JL, et al. Biatrial approach to cardiac myxomas: A 30-year clinical experience. *Ann Thorac Surg* 1995; 59: 851-6.
5. Soeparwata R, Poeml P, Schmid C, Neuhof H, Scheld H. Interleukin-6 plasma levels and tumor size in cardiac myxoma. *J Thorac Cardiovasc Surg* 1996; 112: 1675-77.
6. Ravikumar E, Pawar N, Gnanamuthu R, Sundar P, Cherian M, Thomas S. Access minimal approach for surgical management of cardiac tumors. *Ann Thorac Surg* 2002; 70: 1077-9.
7. Misawa Y, Saito T, Fuse K, Sohara Y. Endoscope-assisted superior septal approach for resection of left atrial myxoma. *J Thorac Cardiovasc Surg* 2002; 123: 357-8.
8. Crafoord C. Discussion of: Glover RP. Late results of mitral commissurotomy. In: Lam CR, editor. *Henry Ford Hospital international symposium on cardiovascular surgery: studies in physiology, diagnosis and techniques: proceedings of the symposium; March 1955; Henry Ford Hospital, Detroit (Michigan)*. Philadelphia: WB Saunders; 1955. p. 202-11.
9. Alkhulaifi AM, Horner S, Pugsley WB, Sturridge MF. Recurrent left atrial myxoma. *Cardiovasc Surg* 1994; 2: 232-6.
10. Attar S, Lee Y-C, Singleton R, et al. Cardiac myxoma. *Ann Thorac Surg* 1980; 29: 397-405.
11. Walton JA Jr, Kahn DR, Willis PW III. Recurrence of a left atrial myxoma. *Am J Cardiol* 1972; 29: 872-6.
12. McCarthy PM, Piehler JM, Schaff HV. The significance of multiple recurrent and "complex" cardiac myxomas. *J Thorac Cardiovasc Surg* 1986; 91: 389-99.
13. Gray IR, Williams WG. Recurring cardiac myxoma. *Br Heart J* 1985; 53: 645-9.
14. Alkhulaifi AM, Horner S, Pugsley WB, Sturridge MF. Recurrent left atrial myxoma. *Cardiovasc Surg* 1994; 2: 232-6.
15. Castells E, Ferran V, Octavio de Toledo MC. Cardiac myxomas: surgical treatment, long-term results and recurrence. *J Cardiovasc Surg* 1993; 34: 49-53.
16. Shinfeld A, Katsumata T, Westaby S. Recurrent cardiac myxoma: seeding or multifocal disease. *Ann Thorac Surg* 1998; 66: 285-8.
17. Bjessmo S, Ivert T. Cardiac myxoma: 40 years' experience in 63 patients. *Ann Thorac Surg* 1997; 63: 697-700.
18. Reynen K. Frequency of primary tumor of the heart. *Am Cardiol* 1996; 77: 107-8.
19. Leonard M. Cardiac tumor: diagnosis and management. *Heart* 2001; 85: 218-22.