

Bile Leakage After T-tube Removal: Report of 3 Cases

Sunthorn Treesaranuwattana MD

Choosak Khemtai MD

Darunee Pimkow MD

St. Mary's Hospital, Nakhon Ratchasima, Thailand

Abstract

Introduction: It is a common practice to drain common bile duct (CBD) by the use of T-tube after supraduodenal choledocholithotomy. The T-tube is removed on the 10th-14th post-operative day following normal findings of post-operative T-tube cholangiogram. Small amount of bile leakage from T-tube tract usually ceases within a few days. In rare instance, persistent biliary leakage may cause bile ascites or bile peritonitis, intraperitoneal collection or biloma and prolonged external biliary drainage or biliary fistula.

Case Reports: We reported our experiences of bile leakage following T-tube removal in three patients who underwent cholecystectomy and exploration of the CBD for gallstones and CBD stones. T-tubes were removed within the 14th-16th post-operative day after normal T-tube cholangiogram findings. One patient was treated simply by percutaneous drainage, the other two patients required endoscopic sphincterotomy and insertion of biliary stent for 3-7 weeks.

Conclusions: Percutaneous drainage and endoscopic procedure are effective treatment in most cases of bile leakage following T-tube removal. Open surgery is needed in bile ascites or bile peritonitis. Bile out flow obstruction should be recognized and managed for the prevention of serious complications from persistent bile leakage.

There are many effective methods employed for removal of common bile duct (CBD) stones. These may include techniques used in traditional surgery, endoscopic surgery, laparoscopic surgery, interventional radiology, extracorporeal shock wave lithotripsy and in certain situation, a combination of these methods. Traditional surgery is still regarded as the standard method to which stones are removed through supraduodenal choledochotomy or transduodenal sphincterotomy or transcystic duct route. Transduodenal approach may be associated with the potential risk of duodenotomy and transcystic duct removal can be done only in limited cases depending upon the size of cystic duct; size, site, number of stones; and the availability of choledochoscopy.¹⁻⁴ In case of

supraduodenal choledochotomy, after completely removal of stones most of surgeons would place a T-tube for drainage of CBD while some surgeons advocate primary closure of CBD without any drainage of CBD or primary suture with transcystic duct drainage (C-tube drainage) or primary closure with internal biliary stenting or choledochoduodenostomy.^{4,7}

The rationales for using a T-tube drainage following CBD exploration are for decompression of CBD in prevention of bile leak during the early postoperative period; providing an access for cholangiographic study; creating an access for further interventional procedure. However, T-tube drainage is known to be associated with some complications⁸⁻¹¹ such as septicemia; increased wound sepsis; pancreatitis; thromboembolism; loss of fluid and electrolytes; and some very rare complications¹²⁻¹⁴ were internal hernia, inflammatory polyp of CBD and left over remnant of

short limb in CBD.

Most authors left T-tube in place for one to three weeks and it was removed when T-tube cholangiogram showed contrast medium freely passing through into duodenum. Two main complications related to T-tube removal are bacteremia and biliary leakage.¹⁵⁻¹⁷ Usually external leakage from T-tube tract will disappear within a few days. In rare instance, bile leak into general peritoneal cavity causing bile ascites or bile peritonitis; loculated in peritoneal cavity forming biloma or loculated abscess; prolonged external leakage as external biliary fistula could be encountered.

CASE REPORTS

This article reported three cases of bile leakage following T-tube removal after a negative T-tube cholangiogram at St. Mary's Hospital during a 6-year period from 1998 to 2003. One of these cases was operated for gallstones and common bile duct exploration at another hospital. During this same period, there were 322 patients operated for gallstones and 55 patients had CBD stones necessitated common bile duct exploration. In our experience, two cases had bile leakage after T-tube removal (Case No. 1 and 2). Case No. 3 was operated at another hospital and was referred to us after having bile leakage following T-tube removal.

Case 1

An 83 year-old man underwent cholecystectomy and exploration of CBD with T-tube drainage for

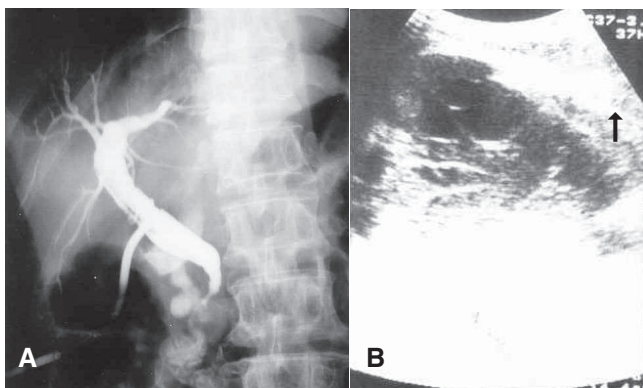


Fig. 1 A Post operative T-tube cholangiogram on day 14 demonstrating a normal tapering at ampullary region and contrast entering duodenum without obstruction. B Ultrasonography showed large loculated fluid collection at right subphrenic space (arrow).

gallstones and CBD stones. Intraoperative cholangiogram and choledochoscopy revealed normal findings. An 8-Fr feeding tube could easily pass into the duodenum without resistance. His postoperative course was uneventful. The T-tube was removed on the 16th postoperative day after a normal T-tube cholangiogram (Figure 1A) on an ambulatory basis. Subsequently, the patient developed abdominal pain within a few hours and was admitted at 36 hours after T-tube removal. On initial evaluation, Body Temp. 38.5°C, Heart rate 100/min, BP 160/70 were noted. He appeared sick and confused. Physical examination revealed no jaundice, moderate tenderness at right upper quadrant and right flank, coarse crepitation was present at right lower lung field. Systemic antibiotics and other supportive treatment were given. Ultrasonography performed on the 3rd day after T-tube removal showed large loculated fluid at right subphrenic space (Figure 1B). Percutaneous drainage by placement of a tube drain under fluoroscopic guide was performed. Initially, 500 ml of bile colored fluid was obtained then it gradually decreased and ceased on the 7th day after drainage. The patient then left the hospital and remained well during the follow-up period of 60 months.

Case 2

A 55 year-old man with history of chronic hepatitis from hepatitis virus B infection two years ago underwent cholecystectomy and exploration of CBD with T-tube drainage for gallstones and CBD stones. Evidences of acute pancreatitis were found at operation. Intraoperative choledochoscopy showed no residual stone but only a 5-Fr feeding tube could pass through the ampulla into duodenum.

The T-tube was removed in the out patient department on the 14th postoperative day after T-tube cholangiogram showed contrast medium freely flowing into duodenum (Figure 2A). Few days later he developed gradual increased abdominal pain and distension with mild tenderness. He also ran a low grade fever course. He was readmitted on the 8th day after T-tube removal. The initial evaluation revealed BP 130/80, Body Temp. 37.5°C, HR 100/min. Physical examination showed mild jaundice, distended abdomen with obvious fluid thrill on the right side. Ultrasonogram showed large amount of loculated fluid in the right side of abdomen. Multiple sites of

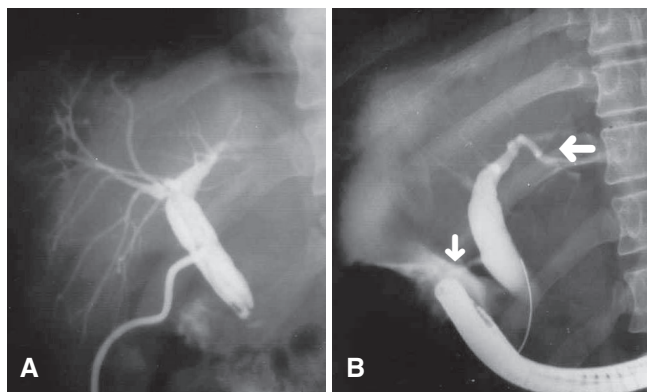


Fig. 2 A T-tube cholangiogram showed some contrast medium entering duodenum but the tapering at sphincter of Oddi region was not demonstrated. B Endoscopic retrograde cholangiogram showed contrast leak from T-tube tract (small arrow) into large loculated collection (large arrow).

percutaneous drainage were performed for placement of drainage tubes under ultrasonographic guide. Approximately 4,500 ml of bile-colored fluid was obtained during the following three days. Endoscopic retrograde cholangiogram performed on the 12th day after T-tube removal revealed contrast leaking from T-tube tract (Figure 2B). Sphincterotomy and biliary stenting with placement of a 7-Fr plastic catheter were performed. Bile leakage ceased within seven weeks, stent was then removed a week later and the patient recovered without any significant abdominal pain or jaundice during the subsequent follow-up of 28 months.

This patient developed abdominal pain, fever with chill and mild jaundice 20 months later. Ultrasonography and computerized tomography (CT) confirmed the presence of a 2-cm CBD stone and he was referred to other institution for lithotripsy and since was lost to our follow-up. This last episode of CBD stone was considered to be a recurrent stone, not a retained stone because of the time interval of up to 4 years.

Case 3

A 77 year-old man underwent cholecystectomy and exploration of CBD with T-tube drainage at other hospital. He was transferred to St. Mary's Hospital in Nakhon Ratchasima because of external bile leakage immediately after T-tube removal on the 14th post-operative day. Review of T-tube cholangiogram showed

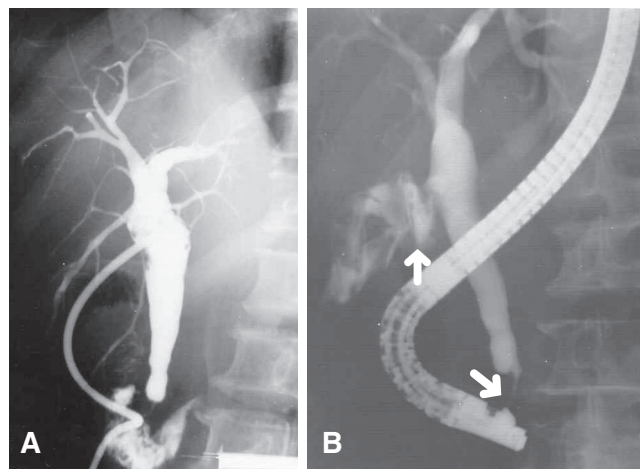


Fig. 3 Endoscopic retrograde cholangiogram showed structural narrowing at sphincter of Oddi area (lower arrow) and contrast leaked from T-tube tract (upper arrow).

contrast medium passing into duodenum but a segment of structural narrowing at the level of sphincter of Oddi was observed. Bile leakage via the T-tube tract was about 400 ml/day. Endoscopic retrograde cholangiogram performed on the 14th day after T-tube removal (Figure 3) confirmed evidence of contrast leak via the T-tube tract. Endoscopic sphincterotomy and biliary stenting with 7-Fr plastic stent were instituted. Following the corrective measure, bile leakage ceased within three weeks. The stent was spontaneously passed in stools a week later. Patient did well without any significant abdominal pain or jaundice during the subsequent follow-up period of 30 months.

DISCUSSION

The incidence of bile leakage after T-tube removal following a negative T-tube cholangiogram varied from 0.8 to 49 per cent depending upon the method of detection. In cases of diagnosis based on initial clinical presentation and confirmed by imaging studies (Ultrasonography, computerized tomography, Scintigraphy) or endoscopy, the incidence was low (0.8-2.2%).^{18,19} Kacker LK, et al²⁰ and Rytov V²¹ reported in the study of bile leakage after T-tube removal by scintigraphy showing evidence of bile leakage in 16 per cent and 30 per cent respectively and most of them were asymptomatic. Domelof L, et al²² performed T-tube cholangiogram with simultaneous fistulogram for studying of

bile leakage. The procedure involved filling contrast medium into T-tube tract after complete filling the biliary tree by continuous injection of contrast during withdrawal of the T-tube. They found that the immediate fistulogram showed contrast leakage from the T-tube tract in 49 per cent but over half of these cases remained asymptomatic.

In current literature, by exclusion of residual stone, major cause of bile leakage after T-tube removal is rupture of the T-tube tract associated with some degree of biliary out flow obstruction suspected to be from sphincter of Oddi dysfunction (SOD). Infective bile is also associated with higher incidence of bile leakage. Rupture of T-tube tract depends on the maturity of the tract related to inflammatory reaction of surrounding tissue. Factors that influence the maturity of T-tube tract include the followings.

1. Time factor Most authors accepted that retaining of T-tube for 10-14 days is adequate for maturity of tract to form. Some authors remove T-tube before 10 days or even on the 4th day, while few report bile leakage after T-tube removal beyond three weeks time.²³ When T-tube cholangiogram shows contrast leaking around T-tube, it must be left in place for another two weeks before repeating T-tube cholangiogram. However, Mosley JG²⁴ reported high incidence of bile leakage after T-tube removal in such situation. In case the patient should need interventional procedure via T-tube tract, it should be retained for an extended period of 4-6 weeks.

2. T-tube factor Latex rubber T-tube can stimulate enough tissue reaction for maturation of the T-tube tract. Polyvinyl chloride (PVC) is less irritating, and thus contributes to less tissue reaction. So it is associated with higher rate of bile leakage after T-tube removal. Shape and size of T-tube are also important factors. When we pull out T-tube for removal, the diameter of the opposed short limbs is larger than the diameter of the long limb or choledochotomy opening leading to traumatic injury to CBD. This factor can be prevented by using of T-tube with sculpt and gutter in V shape at junction of limbs. The small size and guttered-sculpted T-tube needs less force to be removed than a large and virgin T-tube.²⁵⁻²⁷

3. Factor of operative technique Chromic cat gut loose two third of its tensile strength in 10-14 days; it may yield rupture of choledochotomy wound upon pulling of the T-tube. It is advisable to close the

choledochotomy opening with interrupted suture of slow absorbable materials. The intra-abdominal portion of T-tube must be made short and in a relatively straight direction.

4. Systemic factor Conditions associated with slow maturity of T-tube tract include administration of steroid or immunosuppressive drug, radiotherapy, poor nutritional status and ascites.

There are two types of SOD.²⁸⁻³¹ First is functional intermittent obstruction, namely biliary dyskinesia resulted from spasm or hypertrophy or denervation of the sphincter. Second type is structural narrowing at the sphincter of Oddi, namely Oddi sphincter stenosis or ampullary stenosis or papillary stenosis which result from congenital anomaly; inflammatory stricture from frequent passage of stones or operative trauma during CBD exploration; pancreatitis and neoplastic lesion especially early or occult periampullary carcinoma. Hogan and Greenen³² suggested a classification known as Milwaukee biliary group of classification for diagnosis of SOD based on clinical presentation of biliary pain, elevation of liver enzyme over two-time of normal level, dilatation of CBD >12-mm on ultrasonography or >10-mm on endoscopic retrograde cholangiopancreatography (ERCP), delay in emptying of contrast medium >45 min. on ERCP. Recently there has been a surge of interest in sphincter of Oddi manometry as a diagnostic tool. The direct manometric method is performed by cannulation of sphincter and placement the manometric catheter or tip transducer into CBD.

In surgical patient, indirect manometric study can be performed through transcystic duct cannulation or via T-tube. Tondelli and Gyr; Moody FG³³ advocated the measurement of the basal pressure of CBD by cannulation of cystic duct with 5-Fr feeding tube or via T-tube by filling water in tube to 50 cm above zero level at anterior superior iliac spine. The fall of water to 15 cm or below are normal and standard flow through the papilla at a constant pressure of 30 cm is above 14 ml/min. Basal pressure of above 25 cm is a strong suggestion of stenosis. Sounding or gauging the diameter of papilla can also be performed by passage of Bakes dilator. Failure to pass a 3-mm. probe is indicative of stenosis but rigid metal dilator may cause trauma to sphincter that can lead to fibrosis. Moody FG³³ advised that transpapillary passage with 10-Fr soft rubber tube or 5-Fr biliary Fogarty catheter is a much safer maneuver.

High out put volume of bile from T-tube may be

the indicator of partial bile outflow obstruction. A delayed x-ray picture of cholangiogram taken at 45 min. should help to indicate emptying time of contrast from CBD and fistulogram for immediate detection of bile leakage. Biliary leakage initially causes chemical peritonitis or bile ascites and has a mortality rate of around 8 percent, but when bile becomes infected then bile peritonitis with mortality as high as 20 percent may require prompt treatment.³⁴ Jacobs LK, et al³⁵ reported a technique for prevention of serious complication of bile leakage in patient whom T-tube is to be removed by filling the T-tube with contrast material and observing bile leakage under fluoroscopic control while withdrawing T-tube. If extravasation is seen, a guide wire is placed into the T-tube tract and a multiple side-hole tube drain is introduced over the guide wire into the common bile duct for additional two weeks and then repeating this process prior to next attempt. Some authors advise to clamp T-tube for 24 hr prior to removal. If patients suffer pain or develop fever during this time T-tube removal should be delayed.

Treatment of bile leakage after T-tube removal depends on the amount of bile leakage from T-tube tract. Small amount of bile leakage causes minimal clinical sign and symptom which always responds to conservative treatment. Intraperitoneal accumulation such as biloma or loculated abscess can be managed by percutaneous drainage under fluoroscopic or ultrasound guidance. Hartle RL, et al³⁶ reported successful treatment of large biloma and biliary fistula by endoscopic sphincterotomy and biliary stenting without percutaneous drainage. In case of bile ascites or bile peritonitis, re-operation for drainage and peritoneal irrigation with or without reinsertion of T-tube or repair of CBD is rarely required. Although bile leakage can be controlled by any of the above mentioned methods, but patients who have sphincter stenosis should be treated by either endoscopic sphincterotomy or surgical sphincteroplasty.³⁷⁻⁴⁰ When SOD is suspected, absence of structural narrowing of the sphincter does not exclude obstruction especially when there is an absence of normal tapering at ampulla of Vater on T-tube cholangiogram and ampullary biopsy may be necessary for exclusion of early or occult carcinoma.⁴¹ Current trend of treatment seems to have shifted toward minimal invasive endoscopy because of less expensive, short hospital stay and more importantly because of patient preference.

CONCLUSION

Bile leakage after T-tube removal is more common than clinically recognized because small amount of bile leakage ceases soon afterward without causing serious symptom. Studies by scintigraphy or fistulogram revealed an incidence varying from 16-49 per cent leading to a consequence of bile ascites or peritonitis in 0.8 per cent with a mortality of 8-20 per cent depending upon the seriousness of the infectious complication.

Conservative treatment and percutaneous drainage are usually effective for loculated bile leakage. Surgical exploration is needed for bile ascites or peritonitis. Major causes of bile leakage after T-tube removal are rupture of T-tube tract and out flow obstruction or SOD. Rupture of T-tube tract attributed to its maturity is influenced by duration of retaining of T-tube; type, size and materials of the T-tube; surgical technique and patient's general condition. Stenotic type of SOD should be recognized and corrected by either endoscopic sphincterotomy or surgical sphincteroplasty because it increases the chances of having extensive bile leakage from rupture of T-tube tract, prolonged external bile leakage or development of biliary fistula.

REFERENCES

1. Moreaux J. Traditional surgical management of common bile duct stones: a prospective study during a 20-years experience. *Am J Surg* 1995; 169: 220-6.
2. Neoptolemos JP, Davison BR, Lloyd D, Shaw DE, Carr-Lock DL, Fossard DP. Study of common bile duct exploration and endoscopic sphincterotomy in a consecutive series of 438 patients. *Br J Surg* 1987; 74: 916-21.
3. Ihse I, Borch K, Carlsson P, Lindstrom E, Tiseliys HG. Extracorporeal shock wave lithotripsy of bile duct stones. *Acta Chir Scand* 1990; 156: 87-90.
4. Hotta T, Taniguchi K, Kobayashi Y, Johata K, Sahara M, Naka H, et al. Biliary drainage tube evaluation after common bile duct exploration for choledocholithiasis. *Hepato-Gastroenterology* 2003; 50: 315-21.
5. Chen SMS, Chou FF. Choledochotomy for biliary lithiasis: Is routine T-tube drainage necessary. *Acta Chir Scand* 1990; 156:387-390.

6. Mihmanli M, Isgor A, Erzurumlu K, Kabukcuoglu F, Mihmalli I. Long term results of choledochoduodenostomy and T-tube drainage. *Hepato-Gastroenterology* 1996; 43: 1480-3.
7. Uchiyama K, Onishi H, Tani M, Kinishita H, Kawai M, Ueno M, et al. Long term prognosis after treatment of patient with Choledocholithiasis. *Ann Surg* 2003; 238: 97-102.
8. Keighley MRB, Burdon DW, Baddeley RM, Dorricot NJ, Oates GD, Watts GT, et al. Complication of supraduodenal choledochotomy: a comparison of three methods of management. *Br J Surg* 1976; 63: 745-58.
9. Gillatt DA, May RE, Kenedy R, Longstaff AJ. Complications of T-tube drainage of common bile duct. *Ann R Coll Surg Engl* 1985; 67: 370-1.
10. Neoptolemos JP. Complications of T-tube drainage the common bile duct. *Ann R Coll Surg Engl* 1986; 68: 326
11. Lygidakis NJ. Incidence of bile infection in biliary lithiasis. Effect on postoperative bacteremia of choledochoduodenostomy, T-tube drainage, and primary closure of the common bile duct after choledochotomy - a prospective clinical trial. *Am Surg* 1984; 50: 236-40.
12. Watanabe H, Iwase H, Sugitani M. Inflammatory polyp in common bile duct cause by T-tube. *Hepato-Gastroenterology* 2002; 49: 894-6.
13. Thors H, Gudjonsson H, Oddsson E, Cariglia N. Endoscopic retrieval of a biliary T-tube remnant. *Gastrointest Endosc* 1994; 40: 241-2.
14. Fulham SB, Pritchard GA. Internal hernia following T-tube drainage. *Br J Surg* 1985; 72: 519.
15. Lykidakis NJ. Hazard following T-tube removal after choledochotomy. *Surg Gynaecol Obstet* 1986; 163: 153-5.
16. Gharaibeh KIA, Heiss HA. Biliary leakage following T-tube removal. *Int Surg* 2000; 85: 57-63.
17. Galan CP, Alonso AC. Bile leakage after removal of T-tube from common bile duct. *Br J Surg* 1990; 77: 1075.
18. Horgan PG, Campbell AC, Gray GR, Gillespie G. Biliary leakage and peritonitis following removal of T-tube after bile duct exploration. *Br J Surg* 1989; 76: 1296-7.
19. Corbett CRR, Fyfe NCM, Nichol RJ, Jackson BT. Bile peritonitis after removal of T-tube from the common bile duct. *Br J Surg* 1986; 73: 641-3.
20. Kacker LK, Mittal BR, Sikora SS, Ali W, Kapoor VK, Saxena R, et al. Bile leak after T-tube removal - a scintigraphic study. *Hepato-gastroenterology* 1995; 42: 975-8.
21. Rytto N, Rasmussen L, Pedersen SA, Oster-Jorgensen E. 99m Tc-labelled HIDA scintigraphy in assessment of bile leakage after removal of T-tube from the common bile duct. *Br J Surg* 1989; 76: 1319.
22. Demellof L, Rydh A, Truedson H. Leakage from T-tube tracts as determined by contrast radiology. *Br J Surg* 1977; 64: 862-3.
23. Norrby S, Heuman R, Anderberg B, Sjodahl R. Duration of T-tube drainage after exploration of the common bile duct. *Acta Chir Scand* 1988; 154: 113-5.
24. Mosley JG, Barron JA, Holbrook MC, Desai A. An association between leakage of contrast seen on T-tube cholangiogram and subsequent biliary peritonitis. *Br J Radiol* 1992; 65: 185-6.
25. Crnojevic L, Thompson JN, Dudley HAF. T-tube: a comparison of virgin, slit guttered sculpted design. *Br J Surg* 1989; 76: 342-3.
26. Neoptolemos JP. Sculpted T-tubes. *Br J Surg* 1989; 76: 102.
27. Dawyer JL. T-tubes: Virgin, slit, guttered or sculpted. *Br J Surg* 1988; 75: 932.
28. Coelho JCU, Wiederkehr JC. Motility of Oddi's sphincter: recent development and clinical applications. *Am J Surg* 1996; 172: 48-51.
29. Tzovaras G, Rowlands BJ. Diagnosis and treatment of sphincter of Oddi dysfunction. *Br J Surg* 1998; 85: 588-95.
30. Rolny P, Geenen JE, Hogan WJ. Post-cholecystectomy patients with "objective sign" of partial bile outflow obstruction: clinical characteristics, sphincter of Oddi manometry findings, and results of therapy. *Gastrointest Endosc* 1993; 39: 778-81.
31. Chuttani R, Carr-Locke DL. Pathophysiology of the sphincter of Oddi. *Surg Clin N Am* 1993; 73: 1311-22.
32. Hogan WJ, Geenen JE. Biliary dyskinesia. *Endoscopy* 1988; 20: 179-83.
33. Moody FG, Calabuig R, Vecchio R, Runkel N. Stenosis of the sphincter of Oddi. *Surg Clin N Am* 1990; 70: 1341-54.
34. Ackerman NB, Silin LF, Suresh K. Consequences of intraperitoneal bile: Bile ascites versus bile peritonitis. *Am J Surg* 1985; 149: 244-6.
35. Jacobs LK, Shayani V, Sackier JM. Common bile duct T-tube; a caveat and recommendations for management. *Surg Endosc* 1998; 12: 60-2.
36. Hartle RJ, Mc Garrity TJ, Conter RL. Treatment of a giant biloma and bile leak by ERCP stent placement. *Am J Gastroenterol* 1993; 88: 2117-2118.
37. Sugawa C, Park DH, Lucas CE, Higuchi D, Ukawa K. Endoscopic sphincterotomy for stenosis of sphincter of Oddi. *Surg Endosc* 2001; 15: 1004-7.
38. Weitemeyer R. The treatment of ampullary stenosis by endoscopic sphincteromy (EST). *Am J Surg* 1994; 167: 493-6.
39. Nussbaum MS, Warner BW, Saxhc, Fischer JE. Transduodenal sphincteroplasty and trans ampullary septotomy for primary sphincter of Oddi dysfunction. *Am J Surg* 1989; 157: 38-43.
40. Watanapa P, Williamson RCN. Pancreatic sphincterotomy and sphincteroplasty. *Gut* 1992; 33: 865-7.
41. Martin DF. Biopsies of the ampullary region in sphincter of Oddi dysfunction. *Gastrointest Endosc* 1996; 2: 208-9.