

Coloport: An Instrument for Intra-operative Colonic Lavage and Intra-operative Colonoscopy

Wanchai Manakijisirisuthi, MD, FRCST

Division of Surgery, Phetcharat Hospital, Phetchaboon, Thailand

Abstract

Introduction: Obstructed left-sided colonic carcinomas have traditionally been treated by staged operations that carry several disadvantages. The principal objection to primary resection and anastomosis of unprepared bowel is the high incidence of leakage. After Miur had demonstrated that the technique of intra-operative colonic lavage and primary anastomosis was a safe procedure, this technique was later modified by Radcliffe and has now been accepted worldwide. However, the modified technique by Radcliffe has some limitations: it cannot identify the synchronous lesion that may be present somewhere proximal to the obstructing lesion during the operation. The patient needs to have a post-operative colonoscopy to rule out the lesion and risks the second operation if the lesion is found and cannot be removed by the scope. To solve this problem, the Coloport, an instrument used for intra-operative colonic lavage and intra-operative colonoscopy is invented.

Materials and Methods: Coloport is a four-way tube designed as a T-shape tube. The instrument was applied in 15 patients with lesions of the left-sided colon. Fourteen patients had cancer of the colon and rectum; another patient had colonic obstruction by foreign body. All patients were operated with intra-operative colonic lavage and intra-operative colonoscopy followed by primary resection with/without anastomosis. None of them received pre-operative bowel preparation.

Results: Coloport was successfully applied in all cases for intra-operative colonic lavage and intra-operative colonoscopy. The colon was lavaged and clearly visualized with no synchronous lesion detected. Primary anastomosis failed in 2 patients and the patients were left with Hartmann's procedure.

Conclusions: Coloport is a new surgical device. Requiring no meticulous technique to apply, it provides intra-operative colonic lavage and intra-operative colonoscopy the much more convenient procedures.

INTRODUCTION

Obstructed left-sided colon is an emergency condition commonly found in surgical practice. The most common cause of obstruction is carcinoma.¹ Resection with primary anastomosis in an unprepared bowel has a very high incidence of leakage and increased mortality.²⁻⁵ To prevent complications, obstructed left-sided colon has usually been treated by two- or three-staged procedures.⁶⁻⁸ However, staged procedure has

some disadvantages which includes the risk of multiple operations and longer hospital stay from multiple admissions. Furthermore, Fielding and Wells reported that patients with primary resection had a higher 5-year survival than those with staged resections.⁹

Miur EG. introduced the technique of intra-operative colonic lavage and primary anastomosis in patients who presented with left-sided colon obstruction and was shown to be a safe procedure.¹⁰ His technique was later modified by Radcliffe and Dudley, which

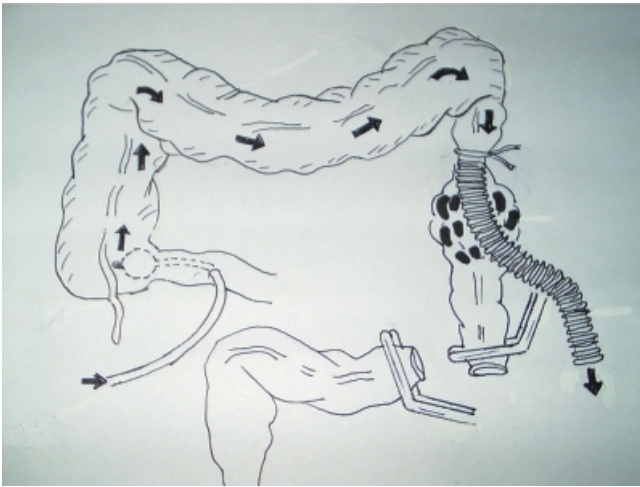


Figure 1 Intra-operative colonic lavage and primary anastomosis in patients with left-sided colon obstruction, modified by Radcliffe and Dudley

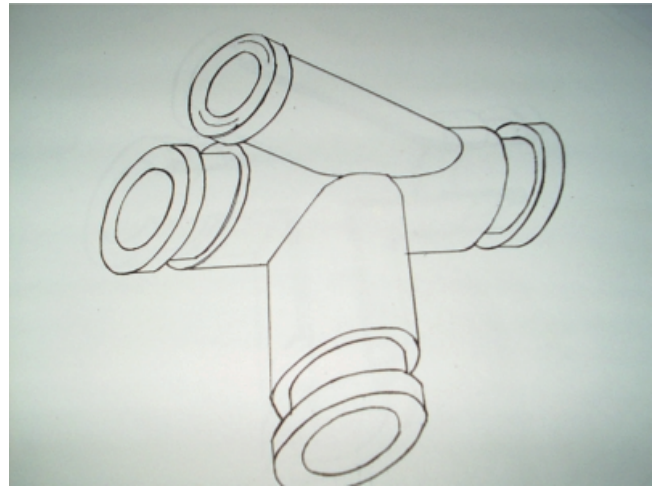


Figure 2 Coloport, a four-way tube, designed as a three-way (T-shape) tube with another smaller fourth tube joining at the "head" of T at 30-degree angle. Both distal ends of the head of "T" lay a groove used for strapping the colon with the instrument

now, has been accepted as a standard treatment for obstructed left-sided colon (Figure 1).¹¹⁻¹⁴

However, the synchronous lesions that may present somewhere proximal to the obstructing part cannot be identified by Radcliffe technique. The incidence of synchronous cancer is about 3-5%¹⁵ whereas the incidence of synchronous polyp may be as high as 30-50%.^{16,17} After the operation, the patient has to re-visit for a colonoscopic examination to rule out the synchronous lesions. If a synchronous lesion is found and cannot be removed via the scope, the patient has to suffer the second operation and risks operative morbidity and mortality.

If we can perform an intra-operative colonic lavage safely, we should find out the way to perform an intra-operative colonoscopy in the same setting. The objective of this study was to present an instrument for intra-operative colonic lavage and intra-operative colonoscopy.

MATERIALS AND METHODS

Coloport is a four-way tube, designed as a three-way (T-shape) tube with another smaller fourth tube joining at the "head" of T at 30-degree angle. Both ends of the head of "T" lay a groove used for strapping the colon with the instrument. All four tubes are thoroughly connected together (Figure 2-4).

Instrument application: After the peritoneal cavity is opened, a routine general exploration is performed.

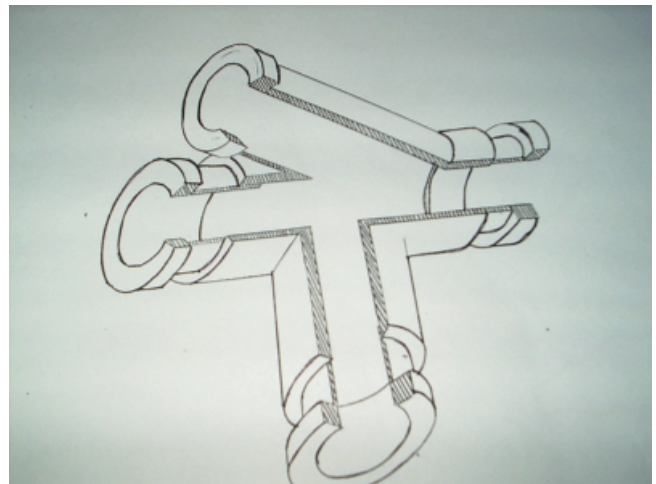


Figure 3 Coloport, all four ways are thoroughly connected together



Figure 4 Coloport

The obstructed lesion is identified and the colon is dissected free as in conventional technique. A segment of colon proximal to the obstructing point, usually 5-10 cm, is selected, clamped and transversely opened (Figure 5). The head of "T" is inserted into the lumen, while the leg of "T" protrudes outside. A cord tape is used to ligate both ends, fixing the colon with the instrument (Figure 6). A sterile bag or a corrugate tube is then connected to the leg of "T" to drain the colonic contents. The smaller fourth tube is then occluded with a gauze pad to prevent leakage of the stool. The intestinal clamps are then removed and fecal material is gradually and manually decompressed

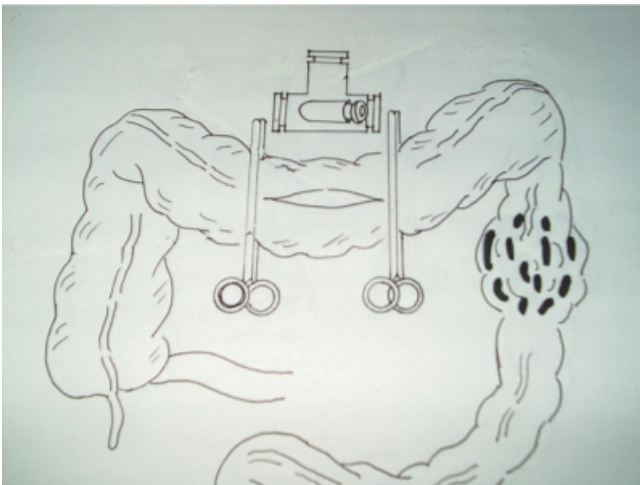


Figure 5 After the obstructed lesion is identified and the colon is dissected free, a segment of colon proximal to the obstructing point, usually 5-10 cm, is selected, clamped and transversely opened

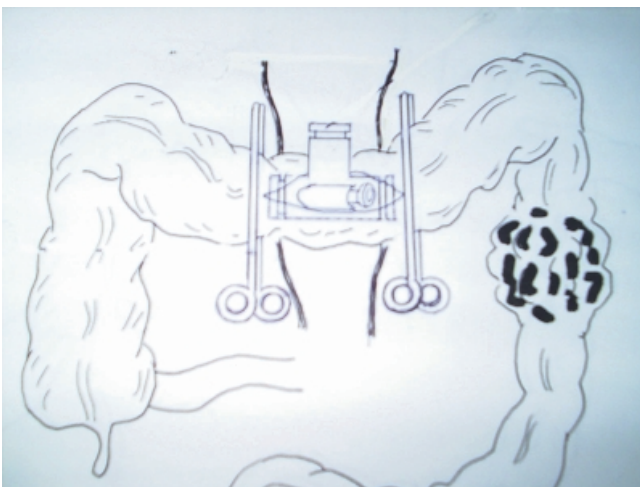


Figure 6 The head of "T" is inserted into the lumen, while the leg of "T" protrudes outside, cord tape is used to ligate both ends, fixing the colon with the device.

into the bag (Figure 7). After the gross fecal content has been evacuated, an NG tube is inserted via the smaller fourth tube and maneuvered to reach the cecum. A piece of gauze pad is packed at the opening of the fourth tube to prevent the spillage. The colon is rinsed with normal saline and manual decompression is repeated until the draining content is clear (Figure 8). The NG tube is then removed and a gastroscope is

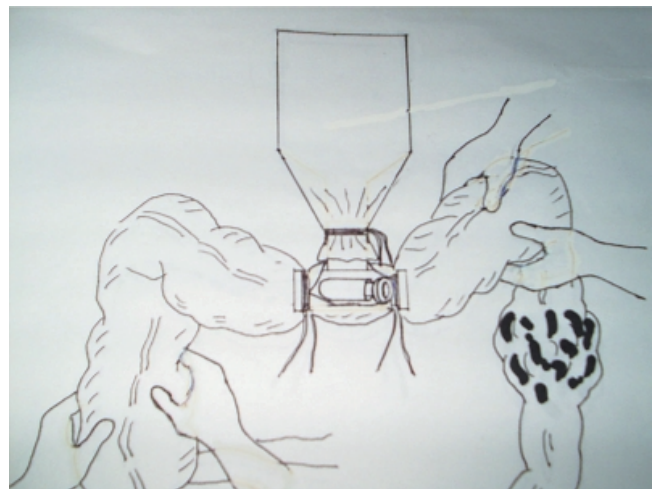

Figure 7 A sterile bag or a corrugate tube connected to the leg of "T" to drain the colonic contents, the smaller fourth tube is occluded with a gauze pad to prevent leakage of the stool, the intestinal clamps are removed and fecal material is gradually and manually decompressed into the bag

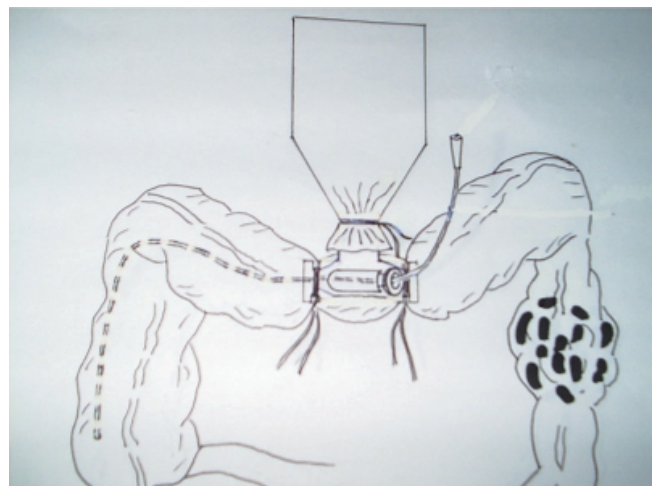


Figure 8 After the gross fecal content has been evacuated, a nasogastric tube is inserted via the smaller fourth tube and maneuvered to reach the cecum, a piece of gauze pad is packed at the opening of the fourth tube to prevent the spillage, normal saline is instilled and manual decompression is repeated until the draining content is clear

introduced to look for a synchronous lesion (Figure 9).

In the condition where the stool is hard or sticky and difficult to decompress through the junction between the head and leg of "T" because of its vertical angle, the technique may be slightly adjusted. One side of the head of "T" is applied into the lumen of colon as usual, while the other side is connected to the corrugated tube. The leg of "T" is closed with a rubber

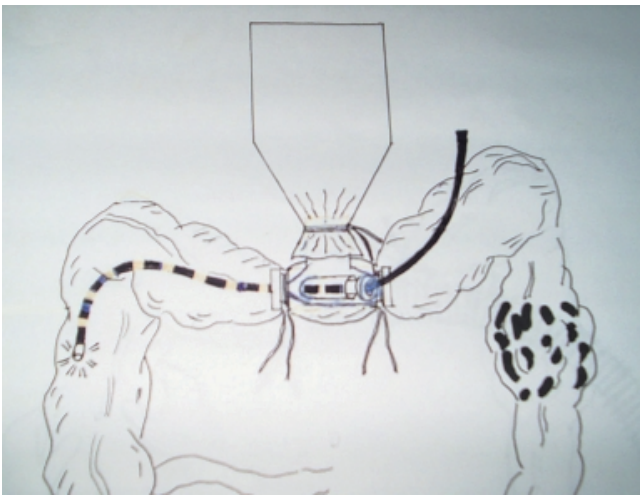


Figure 9 The nasogastric tube is then removed and a gastroscope is introduced to look for a synchronous lesion

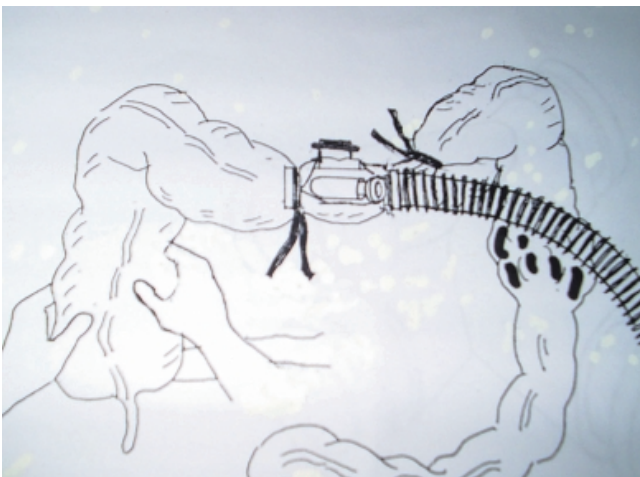

Figure 10 In the condition where the stool is hard or sticky and difficult to decompress through the junction between the head and leg of "T" because of its vertical angle, the technique may be adjusted; one side of the head of "T" is applied into the lumen of colon as usual, while the other side is connected to the corrugated tube, the leg of "T" is closed with a rubber pad to prevent spillage, the fecal material will pass directly from one side to the other side

pad to prevent spillage. The fecal material will pass directly from one side to the other side (Figure 10).

After the colon is completely examined, the obstructed lesion is resected and the anastomoses is performed as in the conventional technique.

RESULTS

From June 6th 2001 to November 5th 2004, the instrument had been applied in 15 patients (12 women and 3 men) with lesions of the left side of the colon. The age ranged from 29-84 years with an average of 61 years. Fourteen patients had colon and rectal cancer and one patient had colonic obstruction from foreign body (santol seeds). None of these patients received pre-operative bowel preparation. The operative procedures being performed included low anterior resection (LAR) in 7 patients, low anterior resection (LAR) with Hartmann's procedure in 2 patients, abdominal-perineal resection in 3 patients, sigmoidectomy in 2 patients and left half colectomy in 1 patient. The gastroscope was successfully applied in all cases and the mucosa was clearly visualized. No synchronous lesion was detected. The operative time ranged from 150-465 minutes with an average of 321 minutes.

DISCUSSION

The steps of manual decompression of fecal material are rather safe with minimal contamination. Fecal spillage may occur during the nasogastric tube and scope insertion and removal. However, a slow and careful manipulation can prevent the spillage. In the future, the fourth tube can be modified to a one-way tube to correct the problem.

Primary anastomosis failed in two patients and the patients ended up with Hartmann's procedure. One patient had a poor blood supply at the proximal end of the colon and was left with Hartmann's colostomy. However, this patient later developed colostomy necrosis and was re-explored to revise the colostomy. Failure in another patient was due to a much disproportion in size between the proximal and distal ends.

Coloport can be applied in both emergency and elective conditions and a pre-operative bowel clearance may be avoided. Usually, the patients need 1-4 days to

stay in the hospital for a pre-operative bowel preparation. The procedure must be carefully monitored to avoid over-hydration or dehydration, especially in patients with underlying heart or renal disease.¹⁸ Another advantage of Coloport is that a gastroscope can be used instead of a colonoscope which may not be available in some hospitals. While applying the scope, the assistant can guide the tip of the scope to the cecum easily. If an abnormal lesion is detected during the procedure, the position of the lesion can be accurately located and removed.

CONCLUSIONS

Coloport is a new device that makes intra-operative colonic lavage a much more convenient procedure. It also enables surgeons to detect a synchronous lesion during the operation and this may help preventing the patient from a second operation.

REFERENCES

- Bunlue C. Adenocarcinoma of colon. In: Bunlue C, editor. *Surgery of colon and rectum*. Bangkok: Rungsilp Printing; 2002. p. 213.
- Schrock TR, Deveney CW, Dunphy JE. Factors contributing to leakage of colonic anastomoses. *Ann Surg* 1973; 513-8.
- Phillips RKS, Hittinger R, Fry JS, Fielding LP. Malignant large bowel obstruction. *Br J Surg* 1985; 72: 296-302.
- Fielding LP, Steward-Brown S, Bleskovsky L. Anastomotic integrity after operation for large bowel cancer: a multi-center study. *Br Med J* 1980; 281: 911-4
- Khoury GA, Waxman BP. Large bowel anastomoses, 1: the healing process and sutured anastomoses: a review. *Br J Surg* 1983; 70: 61-3.
- Deans GT, Krukowski ZH, Irwin ST. Malignant obstruction of the left colon. *Br J Surg* 1994; 81: 1270-6.
- Goligher JC, Smiddy FG. The treatment of acute obstruction or perforation with carcinoma of the colon and rectum. *Br J Surg* 1957; 45: 270-4
- Welch JP, Donaldson GA. Management of severe obstruction of the large bowel due to malignant disease. *Am J Surg* 1974; 127: 472-4.
- Fielding LP, Wells BW. Survival after primary and after staged resection for large bowel obstruction caused by cancer. *Br J Surg* 1974; 61: 16-8.
- Miur EG. Safety in colonic resection. *Proc R Soc Med* 1968; 61: 401-8.
- Radcliffe AG, Dudley HAF. Intraoperative antegrade irrigation of the large intestine. *Surg Gynecol Obstet* 1983; 156: 721-3.
- Allen-Mersh TG. Should primary anastomosis and on-table colonic lavage be standard treatment for left colon emergencies? *Ann Roy Col Surg Eng* 1993; 75: 195-8.
- Dudley HAF, Radcliffe AG, McGeehan D. Intra-operative irrigation of the colon to permit primary anastomosis. *Br J Surg* 1980; 67: 80-1.
- Koruth NM, Krukowski ZH, Youngson GG, et al. Intraoperative colonic irrigation in the management of left-sided large bowel emergencies. *Br J Surg* 1985; 72: 708-11.
- Bunlue C. Adenocarcinoma of colon. In: Bunlue C, editor. *Surgery of Colon and Rectum*. Bangkok: Rungsilp Printing; 2002. p. 217.
- Winawer SJ, O'brian MJ, Waye JD, et al. Risk and surveillance of individuals with colorectal polyps. *Bull WHO* 1990; 68: 789-95.
- Morson BC, Konishi F. Contribution of the pathologist to the radiology and management of colorectal polyps. *Gastrointest Radiol* 1982; 7: 275-81.
- Bunlue C. Bowel preparation. Is it still necessary? In: Prayuth S, Somboon C, Prinya T, editor. *Salyasart Wiwat 32nd* Bangkok: Bangkok Medical Publisher; 2006. p. 290.