

Suction Ligator: An Instrument for Rubber Band Ligation

Wanchai Manakijirsiruthi, MD, FRCST

Division of Surgery, Petcharat Hospital, Petchaboon, Thailand

Abstract

Introduction: Internal hemorrhoid is a common problem in surgical practice. Rubber band ligation usually is recommended for grade II and III internal hemorrhoid and is claimed to be the most effective treatment. Barron's ligator is the instrument of choice; however, one may encounter some problems. Firstly, with improper equipment resulting in poor visualization, to grasp the hemorrhoid at a proper position in the first grasping may not be easy. Secondly, when the hemorrhoid is a large one, the ligator's cup may not cover the entire lesion and thus may render recurrence of the disease. To solve these problems, a suction ligator is designed and developed.

Materials and Methods: The suction ligator composes of 3 parts: loading part, ligating part and handling part. The loading part is a cone-shape piece, used for loading a rubber band. The ligating part is a two-cylindrical tube, inner and outer tube which fit together. The inner tube acts as a sucker that sucks and fixes the hemorrhoid while the outer tube acts as a pusher that pushes and lodges the rubber band. The handling part is a metal tube designed as a handle. It connects the ligating part with a suction unit.

Results: Suction ligator was successfully applied in 40 out-patients with grade II and III internal hemorrhoid during May 2003 and June 2006 without complications. All patients were satisfied with the results.

Conclusions: Suction ligator offers a clear visualization of the hemorrhoid before banding, and thus makes a precise banding. With multisize ligating parts, the instrument can be applied to hemorrhoid of all sizes, small or large. The instrument is modified from cheap basic medical supplies that are readily available in all hospitals.

INTRODUCTION

Internal hemorrhoid is a common disease in surgical practice. Treatment varies from medical to surgical treatment, depending on its severity. Usually, dietary control and medications such as bulk forming agents^{1,2} or micronized purified flavonoids^{3,4} are recommended for first and second degree internal hemorrhoid. However, with persistent bleeding, discomfort or the presence of significant prolapse,

then some other types of treatment are indicated.^{5,6} These include rubber band ligation, injection sclerotherapy, infrared coagulation, bicap coagulation, or cryotherapy. However, the most effective and most popular treatment is rubber band ligation.^{7,8}

Blaisdel was the first to describe the rubber band ligation technique in 1958⁹ but it was Barron who improved the technique and demonstrated its effectiveness in 1963¹⁰. It is now used worldwide because of its simplicity and safety. However, one may

experience some difficulties with the Barron's technique. Firstly, to grasp the hemorrhoid at the proper position (at the head of the hemorrhoid) in the first grasping may not be easy, as the lesions may not be clearly visualized while the surgeon operates through the narrow lumen of the anoscope (Figure 1). If the first grasping is missed, bleeding may occur and may obscure the lesion and may result in an improper banding. Secondly, if the patient has a very large hemorrhoid with the size much larger than the size of the cup of ligator, the banding may not cover the whole lesion and may result in incomplete banding and recurrence of the disease. There's later the introduction of a suction equipped ligator, this instrument can free one hand and allow a better visualization of the anal canal (Figure 2). However, a problem may be faced when one operates on a large hemorrhoid because of the limited size of the cup of ligator. To solve these problems, suction ligator is designed and developed.

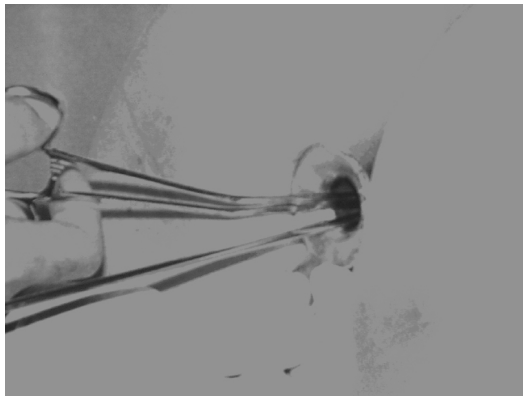


Figure 1 Unclear visualization of the instrument

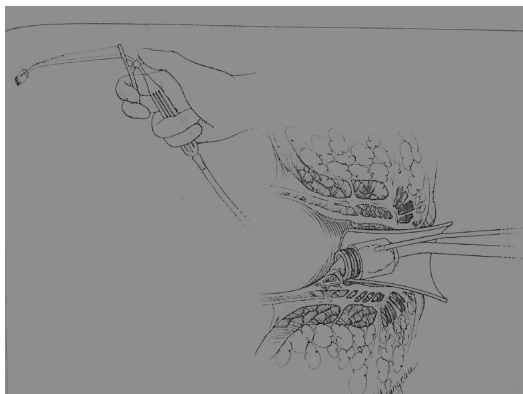


Figure 2 Suction-equipped ligator

MATERIALS AND METHODS

Suction ligator consists of 3 parts: loading part, ligating part and handling part (Figure 3). Loading part is a cone-shaped piece of device, used for loading a rubber band. Ligating part is a pair of cylindrical tubes that fit properly together. The inner tube, on which a rubber band is loaded, functions as a sucking tube that sucks and draws the hemorrhoid into the lumen. The outer tube functions as a pusher that pushes and releases the rubber band to ligate the hemorrhoid. This pair of cylindrical tubes can be adapted from plastic syringes that match together, i.e. 5 and 10 cc syringes or a bigger pair, 10 and 20 cc syringes. Normally, the pair of syringes does not fit properly at first, as there is some space between them and therefore making them unable to release a rubber band. To correct the problem, the cap of the outer syringe is partially cut off that left the lumen approximate the size of inner syringe. This pair of syringes will then fit together perfectly (Figure 4).

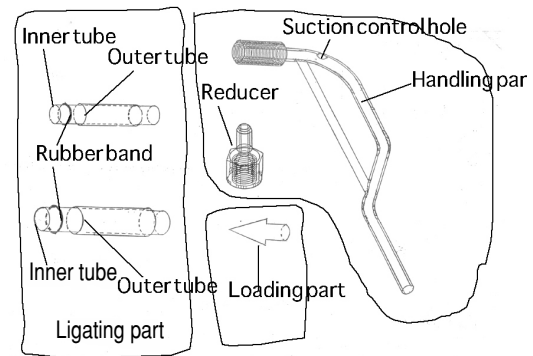


Figure 3 Suction ligator set



Figure 4 Fitting the two syringes together

Handling part is also a tube designed as a handle. One end is connected to the inner tube of the ligating part, while the other end is connected to the suction. There's a hole on the upper part of the handle which is used to control the intensity of suction.

Reducer is an accessory part. It is used when a pair of smaller syringes, 5 and 10 cc is selected.

To apply the instrument, the outer syringe is worn on the inner syringe with the tip of the inner syringe protruded out. The loading part is connected to the tip of inner syringe and a rubber band is loaded on. The other end of the inner syringe is then connected to the handling part which is then connected to the suction unit (Figure 5, 6).

To operate, the patient lies on a Jack-knife position and the anoscope with working space such as Fansler is required (Figure 7). If Fansler is not available, a Sawyer, Ferguson-Moon, Hill-Ferguson or even a vaginal retractor can be used. The anal verge is slightly retracted to reveal the internal hemorrhoid. Once the hemorrhoid is identified and selected, the inner syringe is pushed directly against the hemorrhoid. With the right thumb occluding the hole of the handle (or the

assistant unknings the suction line), the suction pressure increases and the hemorrhoid is sucked and drawn inside (Figure 8). During these steps, the surgeon can see the hemorrhoid clearly through the transparency of the tube. When it reaches the base of hemorrhoid a rubber band is then released by sliding the outer syringe forward with the index finger (Figure 9).

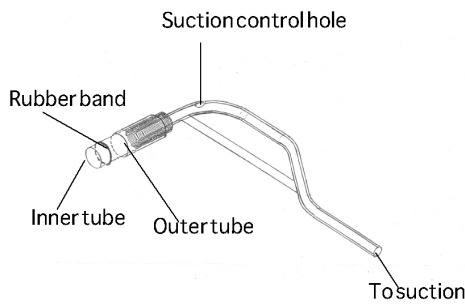


Figure 5 Complete set of suction ligator



Figure 7 Jack-knife position and anoscope with working space required

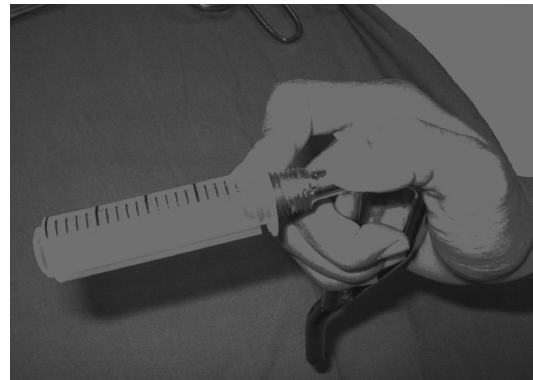

Figure 8 Occluding the hole to suck the hemorrhoid inside

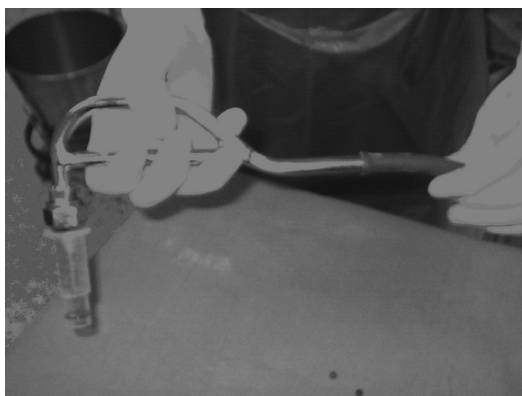

Figure 6 Connection handling part to suction




Figure 9 Sliding the outer tube to release the rubber band

RESULTS

From May 2003 to June 2006, 40 patients from outpatient department were treated with suction ligator. The patients had either grade II or grade III internal hemorrhoid with prolapse or bleeding, but no active bleeding. The banding sites varied from 1 to 3 with the average of 2 sites in one session.

The steps of banding were quite easy and effective since the surgeon could see the hemorrhoid clearly through the transparency of the syringes and thus ligated the hemorrhoid at the proper position. Usually a pair of 5 and 10 cc syringes was selected. However, in cases where the hemorrhoid was large (usually those with third-degree), a pair of 10 and 20 cc syringe was then chosen instead. To use larger pairs, the rubber band was applied from the rubber tube of an intravenous set.

Almost all patients received no anesthesia except for a few who had difficult instrumentation, such as those with previous hemorrhoidectomy or in obese patients with deep natal cleft requiring a hard traction. These patients were locally infiltrated with 1% xylocaine with adrenaline. None of the patients complained of pain but some complained of dull ache and tenesmus during the procedure. However, one old woman felt discomfort while she lied on a jack-knife position. The symptoms persisted and progressed to nausea and dizziness after banding. The band was removed and the patient was admitted for observation and supportive treatment. She was discharged the next morning with no complications. She re-visited and was re-banded the following week. The procedure went on smoothly and the patient was satisfied with the results.

DISCUSSION

Suction ligator offers a clear visualization of the

hemorrhoid during the banding, and thus, one can make a precise banding. With multi-size ligating parts, the instrument can be applied to all size of hemorrhoid, even a large one. The ligating part is modified from plastic syringes which are basic and low cost medical supplies readily available in all hospitals. The instrument is very easy to use without meticulous technique.

REFERENCES

1. Webster DJ, Gough DC, Craven JL. The use of bulky evacuants in patients with haemorrhoids. *Br J Surg* 1978; 65: 291.
2. Mosegaard F, Nielsen MC, Hansen JB, Knudsen JT. High fiber diet reduces bleeding and pain in patients with hemorrhoids. *Dis Colon Rectum* 1982; 25: 454-6.
3. Thanapongsathorn W, Vajjarabukka T. Clinical trial of oral Diosmin (Daflon) in the treatment of hemorrhoids. *Dis Colon Rectum* 1992; 35: 1085-8.
4. Mirsa MC, Parshad R. Randomized clinical trial of micronized flavonoids in the early control of bleeding from acute internal hemorrhoids. *Br J Surg* 2000; 87: 868-72.
5. Chaloeykitti B. Hemorrhoids. In: Chaloeykitti B, editor. *Surgery of colon and rectum*. Bangkok: Rungsilp Printing; 2002. p. 111-3.
6. Thaweechaikarn P. Hemorrhoid. In: Thaweechaikarn P, editor. *Hemorrhoid*. Bangkok: Amarin Printing and Publishing; 2001. p. 62-72.
7. Rojanasakul A. Current practice of hemorrhoid. In: Siriwongs P, Charoensethamaha S, Thaweechaikarn P, editors. *Salyasart Wiwat 32nd*. Bangkok: Bangkok Medical Publisher; 2006. p. 114-5.
8. Jeffrey WM. Hemorrhoidal disease. In: David EB, Steven DW, editors. *Fundamentals of Anorectal Surgery*. New York: McGraw-Hill, Inc.; 1992. p. 198
9. Blaisdell PC. Prevention of massive hemorrhage secondary to hemorrhoidectomy. *Surg Gynecol Obstet* 1958; 106: 485-8.
10. Barron J. Office ligation treatment of hemorrhoids. *Dis Colon Rectum* 1963; 6: 109-13.