

Endoscopic Drainage of Pancreatic Pseudocyst

Montian Marutkarakul, MD
Noppawat Samankatiwat, MD, MSc
Kanes Thongsrisuk, MD
Mongkol Thanarung, MD

Department of Surgery, Ratchaburi Hospital, Ratchaburi, Thailand

Abstract

Background: Endoscopic drainage has become an acceptable alternative to surgical drainage of symptomatic pancreatic pseudocysts. The aim of this study was to evaluate the results of transmural endoscopic drainage procedure at Ratchaburi Hospital, a regional referral center.

Materials and Methods: All patients with pancreatic pseudocysts managed with transmural endoscopic drainage from 2001 through 2006 were retrospectively reviewed. Success rate, complications and recurrence rates were evaluated.

Results: Twelve patients, including 8 males and 4 females, were considered suitable for endoscopic transmural drainage. Successful drainage was achieved in all patients. Complications occurred in 2 patients; one patient had cyst infection and another patient had migration of the stent. There was one early recurrence. All of them were successfully re-drained endoscopically. The median follow-up was 13 months. No further recurrence of the pseudocyst was found.

Conclusions: Endoscopic transmural drainage provides an effective and safe minimally invasive approach to pancreatic pseudocyst management.

INTRODUCTION

Pancreatic pseudocyst is a localized collection of pancreatic secretion enclosed by a non-epithelialized wall, which arises as a result of acute pancreatitis, chronic pancreatitis or pancreatic trauma.¹ Approximately 75% of all cystic lesions of the pancreas are pseudocysts.² Sixteen to 50% of acute pancreatitis and 20%-40% of chronic pancreatitis are complicated with pancreatic pseudocysts.^{3,4} Untreated persistent pseudocysts are associated with 30%-50% complication rates, including abscesses, fistulae, spontaneous

rupture, massive hemorrhage, and death.^{5,6} However, spontaneous resolution of asymptomatic pseudocysts has been shown to occur in approximately 50%-60% of patients managed nonoperatively.^{7,8} Symptomatic pseudocyst can be drained percutaneously, surgically, or endoscopically. Endoscopic drainage of pancreatic pseudocysts can be performed by transpapillary or transmural (transgastric or transduodenal) approach. The transmural approach includes EUS-guided and non-EUS guided drainage. The aim of this study was to evaluate the results of non-EUS guided transmural endoscopic drainage procedure at Ratchaburi Hospital.

Presented at the Joint Meeting of the 31st Annual Scientific Meeting of the Royal College of Surgeons of Thailand and the International Society of Surgery, Ambassador City Jomtien Hotel, Pattaya, Thailand, 7-10 July 2006

Correspondence address: Montian Marutkarakul, MD, Department of Surgery, Ratchaburi Hospital, Ratchaburi 70000, Thailand,
E-mail address: montian007@yahoo.com

PATIENTS AND METHODS

Clinical and procedural details from all patients with symptomatic pancreatic pseudocysts managed with transmural endoscopic drainage at Ratchaburi Hospital between May 2001 and July 2006 were retrospectively studied. Pancreatic pseudocysts were diagnosed by ultrasonography and computed tomography (CT) (Figure 1). During this period, 12 patients (8 males and 4 females) with median age of 41.5 years (range 11-60 years) were considered suitable for non-EUS guided transmural endoscopic drainage. Inclusion criteria included the absence of a large amount of debris or mass within the pseudocyst, pseudocyst wall less than 1 cm in thickness, and identification of obvious extrinsic compression of the posterior wall of the stomach or first part of the duodenum. All patients were symptomatic.

The etiologies of pseudocysts included alcoholic pancreatitis in 9, gallstone in 1 and trauma in 2 patients. Pseudocysts were located in the head (n = 4) and body (n = 8) of the pancreas and ranged from 7 to 20 cm in diameter (median 12 cm). ERCP was attempted in 7 patients and successful cannulation of the pancreatic duct was achieved in 4 patients. All failures were due to duodenal compression. Evidence of pseudocyst connection with the main pancreatic duct was present in all patients but no obvious communication was seen.

Technique

The whole procedure was performed under general anesthesia with endotracheal intubation. All

patients received broad-spectrum prophylactic antibiotics. Endoscopy was performed using a side viewing video-endoscope. Pseudocyst can be identified by an obvious extrinsic compression or bulging of the posterior wall of the stomach or first part of the duodenum (Figure 2A). Subsequently, the pseudocyst was punctured using a needle knife papillotome at the point of maximal prominence (Figure 2B). Entering the pseudocyst was confirmed by free flow of fluid from the collection. The catheter was then advanced into the cavity to maintain the opening of the orifice. Contrast medium was subsequently injected to confirm the position. A 0.035-inch guidewire was inserted into the pseudocyst and coiled into the collection (Figure 2C). The tract was enlarged with a sphincterotome or a balloon up to the diameter of 8 mm if multiple-stent insertion was planned (Figure 2D-2E). Moreover, gastric content was evacuated through the endoscope to decrease the risk of aspiration. Finally one or two double pigtail stents were inserted to ensure adequate drainage (Figure 2F).

Follow-up

Patients were followed clinically and with ultrasonography and CT scan. Stents were removed endoscopically if CT scan showed resolution of the pseudocyst (Figure 3). The median follow-up was 13 months (range 4-47 months). One patient died of end stage liver disease.

RESULTS

Endoscopic drainage was performed in 12 patients; via the stomach (endoscopic cystgastrostomy) in 8 and the duodenum (endoscopic cystduodenostomy) in 4. There was no clinical failure. Indications for drainage included pain related to the collection (100%) and cyst infection (16.6%). Two patients (16.6%) had both conditions. Median pseudocyst size was 12 cm (range 7-20 cm) (Table 1). Successful drainage was achieved in all patients with 2 double pigtail stents in 2 patients (16.6%) and 1 double pigtail stent in 10 patients (83.4%). In the latter group, drainage was achieved with a 10-Fr double pigtail stent in 40% of the patients and a 7-Fr double pigtail stent in 60%. Six patients underwent fluid aspiration for Gram's stain and culture. Fluid amylase level was

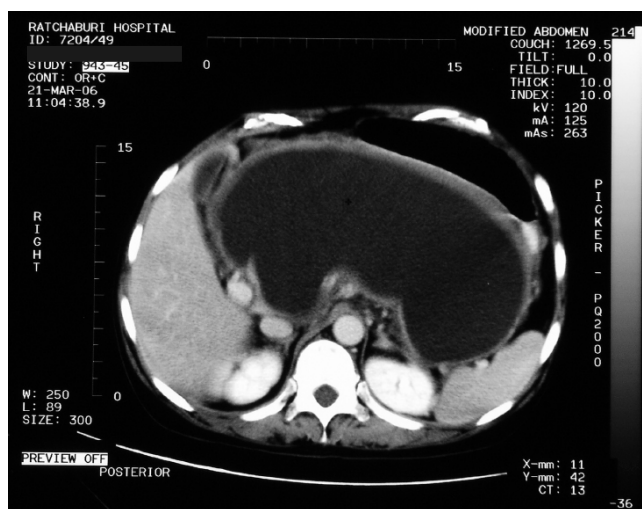


Figure 1 Large pancreatic pseudocyst compressing the stomach

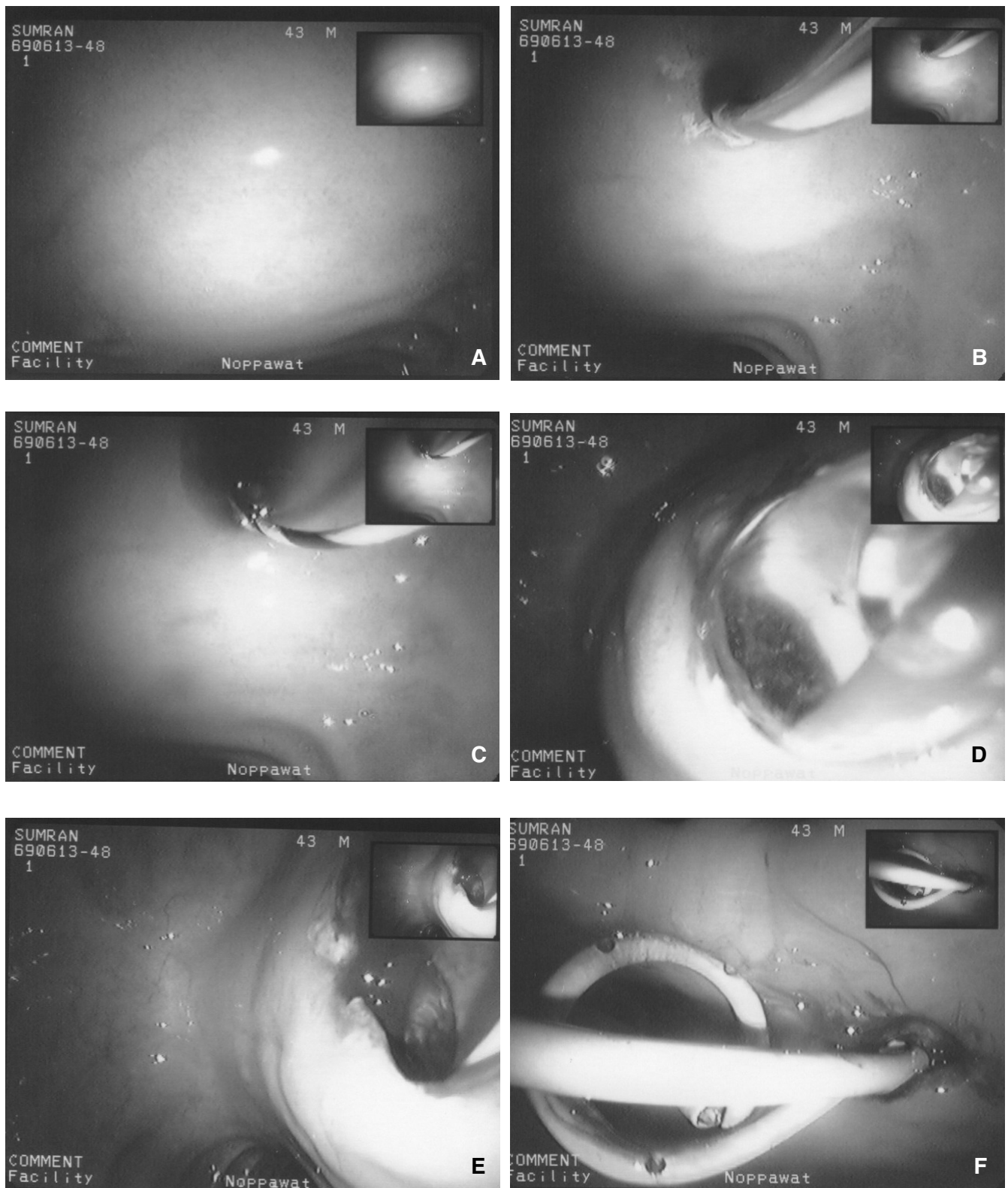


Figure 2 A Extrinsic compression of the duodenum
 B Puncture of pseudocyst with needle-knife papillotome, guide wire passed into catheter
 C Guide wire placed through the duodenal wall into the pseudocyst
 D Dilation of the cystoduodenostomy with 8-mm dilation balloon over the guide wire
 E Pseudocyst-duodenostomy fistula after balloon dilation
 F Two double-pigtail stents placed through the cystoduodenostomy

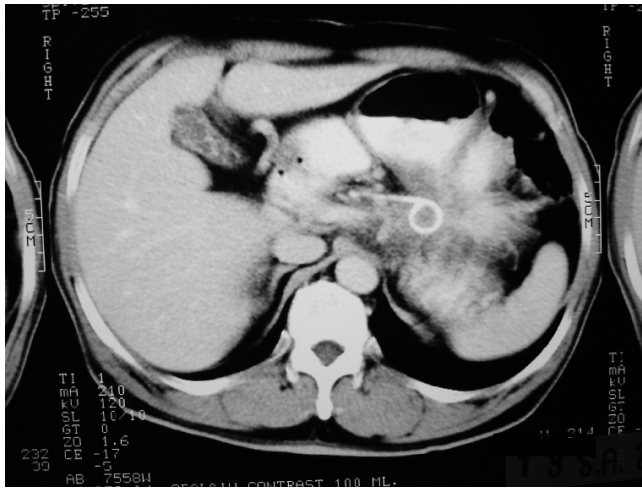


Figure 3 Repeated abdominal CT in patient #7, 3 months post endoscopic cystenterostomy, showing resolution of the pseudocyst

measured in three patients in order to confirm the diagnosis of pseudocyst. Complications occurred in 2 patients (16.6%) (secondary cyst infection in 1 and stent migration in 1). The patient with cyst infection was successfully treated by secondary endoscopic drainage and intravenous antibiotics. Another patient was treated by reinsertion of the stent.

There was 1 patient with inadequate drainage (8.3%). This patient was successfully re-drained using endoscopic technique. Factors associated with inadequate drainage and secondary cyst infection included one small (7-Fr) stent insertion (n = 2), infected pseudocyst (n = 1), endoscopic cystgastrostomy (n = 2). No procedure-related mortality was found. The median follow-up was 13 months. No further recurrence of the pseudocyst was found (Table 2).

Table 1 Characteristics in 12 patients with endoscopic transmural pseudocyst drainage

Patient	Age (yr)	Gender	Etiology	Indication	Size (cm) (maximum)	Location	Approach
1	23	M	Alcohol	Abdominal pain	10	Head	Transduodenal
2	60	M	Gallstone	Abdominal pain, Infected pseudocyst	15	Body	Transgastric
3	45	F	Alcohol	Abdominal pain	9	Body	Transgastric
4	32	M	Trauma	Abdominal pain	10	Body	Transgastric
5	37	M	Alcohol	Abdominal pain	12	Body	Transgastric
6	58	F	Alcohol	Abdominal pain, Infected pseudocyst	10	Body	Transgastric
7	56	M	Alcohol	Abdominal pain	16	Body	Transgastric
8	50	M	Alcohol	Abdominal pain	7	Head	Transduodenal
9	11	F	Trauma	Abdominal pain	13	Body	Transgastric
10	43	M	Alcohol	Abdominal pain	12	Head	Transduodenal
11	29	M	Alcohol	Abdominal pain	20	Body	Transgastric
12	40	F	Alcohol	Abdominal pain	20	Head	Transduodenal

Table 2 Outcomes in 12 patients with endoscopic transmural pseudocyst drainage

Patient	Approach	Complications	Follow-up (months)	Recurrence	Repeat endoscopic drainage	Stent size/number
1	Transduodenal	No	40	No	No	7Fr × 1
2	Transgastric	No	20	No	No	10Fr × 1
3	Transgastric	No	47	No	No	10Fr × 1
4	Transgastric	No	4	No	No	7Fr × 1
5	Transgastric	Stent migration	32	No	Yes	7Fr × 1, 10Fr × 1
6	Transgastric	No	15	Yes	Yes	7Fr × 1, 10Fr × 2
7	Transgastric	No	14	No	No	7Fr × 1
8	Transduodenal	No	12	No	No	10Fr × 1
9	Transgastric	No	10	No	No	10Fr × 1
10	Transduodenal	No	9	No	No	7Fr + 10Fr
11	Transgastric	Infection	8	No	Yes	7Fr, 10Fr
12	Transduodenal	No	7	No	No	10Fr × 2

DISCUSSION

Pancreatic pseudocyst is the most common complication of acute and chronic pancreatitis.⁹ Symptomatic, persistent (>6 weeks), enlarging and complicated cysts are indications for interventional therapy.^{10,11} Intervention is recommended after an observation period of at least 6 weeks, as in many cases, the cyst resolve spontaneously during this time.^{7,8} There are various treatment modalities including surgical, laparoscopic, percutaneous and endoscopic drainage.

Surgical drainage has been considered the gold standard approach with recurrent rates as low as 0-8%, major complication rate approximately 9% and mortality 0-3%.¹²⁻¹⁴ In pseudocyst associated with alcoholic pancreatitis, most of the patients has chronic pancreatitis in which the continuing of disease process or failure to correct the underlying cause are main reasons for recurrence rather than an inadequate drainage.^{15,16} In recent series, surgical drainage is usually reserved for complicated pseudocysts, cysts with failed non-surgical treatment, recurrent cyst or pseudocyst involving adjacent organ.^{15,17,18}

Percutaneous drainage has several disadvantages including skin problems, bleeding, secondary infection and the potential for development of an external pancreatic fistula after drain removal.¹⁹⁻²⁵ Adjunctive octreotide therapy may decrease fistulous output and the length of catheter drainage. It also allows safe removal of the catheter without risk of pseudocyst recurrence.^{24,26} Percutaneous drainage should be reserved for poor-risk patients, immature cysts, patients with infected pancreatic pseudocysts, or as adjuvant treatment with endoscopic or surgical drainage.^{10,19,21,27}

Endoscopic drainage of pancreatic pseudocysts has been reported for more than 2 decades ago.^{28,29} Endoscopic drainage has become a more common treatment modality of symptomatic pseudocyst. Endoscopically, the pseudocyst can be drained either by transpapillary or cyst-enterostomy, or both. The safety and efficacy of endoscopic drainage of pancreatic pseudocyst has been reported in several series.³⁰⁻³⁹

Transpapillary drainage is used primarily for pseudocysts that communicate with the pancreatic duct, which occurs in 40%-80%,⁴⁰⁻⁴³ although not all of these are feasible for transpapillary drainage. High success rate has been reported between 80%-90%, with long-term recurrence rate of 5%-15%.^{32,34-36,44} Complications, including bleeding, pancreatitis, stent

migration, stent obstruction and infection, occur in less than 15% of reported cases.⁴³ Despite a communication between the pancreatic duct and the pseudocyst, some endoscopists still prefer transmural drainage rather than transpapillary one.^{30,45} Potential serious complications were infection and acute pancreatitis. Furthermore, ERCP is frequently difficult owing to compression and distortion of the pylorus and duodenum. Therefore, ERCP was not performed routinely in our institute. In this series, ERCP was attempted in 7 patients and successful cannulation of the pancreatic duct was achieved in 4 patients. Failures were due to duodenal compression. Connection between pseudocyst and the main pancreatic duct was present in all patients but the exact location could not be identified. Treatment choices did not depend on the presence of the communication between cyst and pancreatic duct, as we performed endoscopic drainage only when obvious extrinsic compressions or bulges in the posterior wall of the stomach or first part of the duodenum were identified. Sharma and colleagues recommended that ERCP was only required if transmural drainage was not possible, when the patient was symptomatic after drainage of the cyst, and to prevent recurrence of pancreatitis in the biliary group if there is suspicious of CBD stones.¹⁶ Additionally, the presence of pancreatic ascites in patients with pancreatic pseudocyst is also an indication for ERCP.⁴⁰ Transpapillary drainage is the treatment of choice in a communicating pseudocyst smaller than 6 cm and remotes from gastric and duodenal wall.⁴⁶ Precisely, this procedure is usually only possible for the pseudocyst of the pancreatic head.¹⁸ Long-term transpapillary drainage has been associated with stent occlusion, the need for additional endoscopic procedures and the potential of ductal damage in patient whose pancreatic duct is otherwise normal.^{45,47}

Transmural drainage of pancreatic pseudocyst is accomplished by placing one or more large-bore stents through the gastric or duodenal wall. This approach can be performed either with or without endoscopic ultrasonography (EUS) guidance. Due to the fact that EUS was not available at our institution, conventional endoscopic transmural drainage was then performed. Pseudocysts with wall thickness less than 1 cm and a visible bulging into the stomach or duodenum were considered for drainage. The procedure was technically successful in all patients in our study. Careful patient

selection is one of possible key factors of success. Endoscopic drainage was not applied if such definite bulging was not identified by imaging or endoscopy. However, in this circumstance, pseudocyst drainage under EUS guidance could be done by many investigators.^{18,45,46,48-51} Therefore, some endoscopists consider routine EUS before pseudocyst drainage an unnecessary.⁵²⁻⁵⁴

The complication rate was 16.6 % which was comparable with previous studies.^{16,30,34-36,38,39,44,55,56} In our series, 1 patient with secondary cyst infection was observed. The patient underwent endoscopic cystgastrostomy with 7-Fr double pigtail stent insertion. Nevertheless, results from several reports showed that single 7-Fr endoprosthesis placement is insufficient to drain pseudocyst effectively and might promote cyst infection either due to the endoscopic procedure itself or inadequate drainage.^{18,27,47,58} Currently, we routinely insert at least two large pigtail stents.

Stent migration was observed in one patient. We prefer the use of double pigtail stents instead of straight stents as the pigtail configuration should ensure the position of the stent. In this series, factor that might have contributed to stent migration was the size of endoscopic cystgastrostomy. Difficulty and poor stent placement, especially placement of only one stent, may be encountered in those who have a large orifice of cystgastrostomy, as the stent can be easily dislodged.

Bleeding and perforation are the most serious complications after endoscopic drainage (6%-16%).^{35,36,38,49,54} All of these complications were not seen in our series. This might be due to appropriate patient selection and double-pigtail stent insertion. The pigtail configuration ensures the position of the stent and is less likely to erode into the cyst wall, so it prevents perforation and decreases bleeding complication.⁵⁵ EUS may reduce these complications, especially in pseudocyst with intervening vessels and no endoluminal bulge,^{31,35,45,46,50} but EUS cannot prevent bleeding from vessels or pseudoaneurysms in the wall of pseudocyst.^{18,53} Another important factor is balloon dilation of the fistula tract. Norton et al reported that risk of hemorrhage and infection may be reduced by using balloon dilation.⁵³ Enlargement of the initial puncture by cautery is thought to increase the risk of bleeding. We now propose balloon dilation of transmural tract.

In this series, one patient (8.3%) underwent

second endoscopic drainage because of inadequate drainage. This is comparable with those of previous reports.^{16,27,30,38,39,55,56} Many factors contribute to insufficient cyst resolution in our series. The patient with early recurrence had infected pseudocyst which often considered unsuitable for endoscopic drainage.^{57,58} We performed endoscopic drainage of infected pseudocyst in two patients and in one secondary infected pseudocyst. Although, there is limited experience with endoscopic management of infected pseudocysts, patients with primary and secondary cyst infection required aggressive endoscopic management, such as placement of multiple stents, a nasocystic catheter for cyst irrigation, or endoscopic debridement.^{34,43,46,51,55,59} However, infected pancreatic pseudocyst could successfully be treated by transmural drainage with stent insertion without nasocystic drainage.⁶⁰

Another factor contributing to the success was simultaneous insertion of multiple endoprosthesis. In all of our patients who required secondary endoscopic drainage, only one 7-Fr double pigtail stent was inserted. Although chronic cyst with clear liquid content can be drained with a single stent,^{35,46} placement of more than one stent may assure a wider drainage opening and allow the cyst-enterostomy tract to remain open longer.⁵⁵ In addition, in multiple endoprostheses insertion, the contents can be drained not only through, but also around and between the stents and this appears to result in better drainage, even in the case of stent occlusion.^{18,53} We now insert at least 2 large double pigtail stents.

All of re-endoscopic cases in our series underwent endoscopic cystgastrostomy. Previous studies reported a more success rate after transduodenal drainage in comparison with transgastric route and transduodenal drainage may be considered as the treatment of choice for pseudocyst located close to the duodenum.^{30,33,35,38,55} Long-term patency of cystoduodenal fistula and paraduodenal pseudocysts which may be smaller than paragastric pseudocysts could result in a lower risk of infection and recurrence.^{30,35,61} However, some authors have claimed that transpapillary drainage is less invasive and safer; they reserved transmural drainage for patients who were not suitable for transpapillary drainage.^{34,36,44}

Existing published experience with endoscopic drainage of trauma-related pseudocysts is very limited.

In our series of two trauma-related pseudocysts, there were no complications or recurrences. It is possible that there was a major duct transection resulting in atrophy of the distal pancreas and this may be responsible for the absence of recurrence.¹⁶ Thus, regarding traumatic pseudocysts, further large scale studies are needed to clarify the rate of recurrence.

CONCLUSIONS

Endoscopic transmural pseudocyst drainage is an effective and safe treatment modality, especially in bulging pseudocyst and pseudocyst with wall thickness less than 1 cm. It has low complication and recurrent rates with a high success rate, without the need of routine pancreatogram to identify ductal communication and to perform transpapillary drainage. Double pigtail endoprosthesis should be used to avoid pressure necrosis of the cyst wall, causing perforation or severe bleeding. Importantly, indwelling of multiple large endoprosthesis for at least 6 weeks is advisable. Nasocystic catheter and prolonged irrigation were necessary for infected pancreatic pseudocyst. Furthermore, the presence of tissue debris requires more aggressive approaches, for instance, endoscopic debridement. Appropriate surgical facilities are also essential. Open surgery should be reserved for those patients in whom minimal invasive therapy is unsuccessful.

REFERENCES

- Bradley EL, III. A clinically based classification system for acute pancreatitis. Summary of the International Symposium on Acute Pancreatitis, Atlanta, Ga. September 11 through 13, 1992. *Arch Surg* 1993;128:586-90.
- Yeo CJ, Sarr MG. Cystic and pseudocystic diseases of the pancreas. *Curr Probl Surg* 1994;31:165-243.
- Grace PA, Williamson RC. Modern management of pancreatic pseudocysts. *Br J Surg* 1993;80:573-81.
- Bartoli E, Delcenserie R, Yzet T, et al. Endoscopic treatment of chronic pancreatitis. *Gastroenterol Clin Biol* 2005;29:515-21.
- Bradley EL, Clements JL Jr, Gonzalez AC. The natural history of pancreatic pseudocysts: a unified concept of management. *Am J Surg* 1979;137:135-41.
- Wade JW. Twenty-five year experience with pancreatic pseudocysts. Are we making progress? *Am J Surg* 1985;149:705-8.
- Yeo CJ, Bastidas JA, Lynch-Nyhan A, Fishman EK, Zinner MJ, Cameron JL. The natural history of pancreatic pseudocysts documented by computed tomography. *Surg Gynecol Obstet* 1990;170:411-7.
- Vitas GJ, Sarr MG. Selected management of pancreatic pseudocysts: operative versus expectant management. *Surgery* 1992;111:123-30.
- D'Egidio A, Schein M. Pancreatic pseudocysts: a proposed classification and its management implications. *Br J Surg* 1991;78:981-4.
- Bhattacharya D, Ammori BJ. Minimally invasive approaches to the management of pancreatic pseudocysts: review of the literature. *Surg Laparosc Endosc Percutan Tech* 2003;13:141-8.
- Pitchumoni CS, Agarwal N. Pancreatic pseudocysts. When and how should drainage be performed? *Gastroenterol Clin North Am* 1999;28:615-39.
- Lohr-Happe A, Peiper M, Lankisch PG. Natural course of operated pseudocysts in chronic pancreatitis. *Gut* 1994;35:1479-82.
- Parks RW, Tzovaras G, Diamond T, Rowlands BJ. Management of pancreatic pseudocysts. *Ann R Coll Surg Engl* 2000;82:383-7.
- Usatoff V, Brancatisano R, Williamson RC. Operative treatment of pseudocysts in patients with chronic pancreatitis. *Br J Surg* 2000;87:1494-9.
- Cooperman AM. Surgical treatment of pancreatic pseudocysts. *Surg Clin North Am* 2001;81:411-9, xii.
- Sharma SS, Bhargawa N, Govil A. Endoscopic management of pancreatic pseudocyst: a long-term follow-up. *Endoscopy* 2002;34:203-7.
- Brugge WR. Approaches to the drainage of pancreatic pseudocysts. *Curr Opin Gastroenterol* 2004;20:488-92.
- Fockens P. EUS in drainage of pancreatic pseudocysts. *Gastrointest Endosc* 2002;56:S93-S97.
- Neff R. Pancreatic pseudocysts and fluid collections: percutaneous approaches. *Surg Clin North Am* 2001;81:399-403, xii.
- Freeny PC, Lewis GP, Traverso LW, Ryan JA. Infected pancreatic fluid collections: percutaneous catheter drainage. *Radiology* 1988;167:435-41.
- vanSonnenberg E, Wittich GR, Casola G, et al. Percutaneous drainage of infected and noninfected pancreatic pseudocysts: experience in 101 cases. *Radiology* 1989;170:757-61.
- Ahearne PM, Baillie JM, Cotton PB, Baker ME, Meyers WC, Pappas TN. An endoscopic retrograde cholangiopancreatography (ERCP)-based algorithm for the management of pancreatic pseudocysts. *Am J Surg* 1992;163:111-5.
- Adams DB, Anderson MC. Percutaneous catheter drainage compared with internal drainage in the management of pancreatic pseudocyst. *Ann Surg* 1992;215:571-6.
- D'Agostino HB, vanSonnenberg E, Sanchez RB, Goodacre

- BW, Villaveiran RG, Lyche K. Treatment of pancreatic pseudocysts with percutaneous drainage and octreotide. Work in progress. *Radiology* 1993;187:685-8.
25. Heider R, Meyer AA, Galanko JA, Behrns KE. Percutaneous drainage of pancreatic pseudocysts is associated with a higher failure rate than surgical treatment in unselected patients. *Ann Surg* 1999;229:781-7.
 26. Lansden FT, Adams DB, Anderson MC. Treatment of external pancreatic fistulas with somatostatin. Second place winner: Conrad Jobst award. *Am Surg* 1989;55:695-8.
 27. Baron TH, Harewood GC, Morgan DE, Yates MR. Outcome differences after endoscopic drainage of pancreatic necrosis, acute pancreatic pseudocysts, and chronic pancreatic pseudocysts. *Gastrointest Endosc* 2002;56:7-17.
 28. Hershfield NB. Drainage of a pancreatic pseudocyst at ERCP. *Gastrointest Endosc* 1984;30:269-70.
 29. Kozarek RA, Brayko CM, Harlan J, Sanowski RA, Cintora I, Kovac A. Endoscopic drainage of pancreatic pseudocysts. *Gastrointest Endosc* 1985;31:322-7.
 30. Cremer M, Deviere J, Engelholm L. Endoscopic management of cysts and pseudocysts in chronic pancreatitis: long-term follow-up after 7 years of experience. *Gastrointest Endosc* 1989;35:1-9.
 31. Grimm H, Meyer WH, Nam VC, Soehendra N. New modalities for treating chronic pancreatitis. *Endoscopy* 1989;21:70-4.
 32. Kozarek RA, Ball TJ, Patterson DJ, Freeny PC, Ryan JA, Traverso LW. Endoscopic transpapillary therapy for disrupted pancreatic duct and peripancreatic fluid collections. *Gastroenterology* 1991;100:1362-70.
 33. Sahel J. Endoscopic drainage of pancreatic cysts. *Endoscopy* 1991;23:181-4.
 34. Catalano MF, Geenen JE, Schmalz MJ, Johnson GK, Dean RS, Hogan WJ. Treatment of pancreatic pseudocysts with ductal communication by transpapillary pancreatic duct endoprosthesis. *Gastrointest Endosc* 1995;42:214-8.
 35. Smits ME, Rauws EA, Tytgat GN, Huibregtse K. The efficacy of endoscopic treatment of pancreatic pseudocysts. *Gastrointest Endosc* 1995;42:202-7.
 36. Binmoeller KF, Seifert H, Walter A, Soehendra N. Transpapillary and transmural drainage of pancreatic pseudocysts. *Gastrointest Endosc* 1995;42:219-24.
 37. Howell DA, Elton E, Parsons WG. Endoscopic management of pseudocysts of the pancreas. *Gastrointest Endosc Clin N Am* 1998;8:143-62.
 38. Beckingham IJ, Krige JE, Bornman PC, Terblanche J. Long term outcome of endoscopic drainage of pancreatic pseudocysts. *Am J Gastroenterol* 1999;94:71-4.
 39. Vitale GC, Lawhon JC, Larson GM, Harrell DJ, Reed DN, Jr., MacLeod S. Endoscopic drainage of the pancreatic pseudocyst. *Surgery* 1999;126:616-21.
 40. Laxson LC, Fromkes JJ, Cooperman M. Endoscopic retrograde cholangiopancreatography in the management of pancreatic pseudocysts. *Am J Surg* 1985;150:683-6.
 41. Sahel J, Bastid C, Pellat B, Schurgers P, Sarles H. Endoscopic cystoduodenostomy of cysts of chronic calcifying pancreatitis: a report of 20 cases. *Pancreas* 1987;2:447-53.
 42. Nealon WH, Townsend CM, Jr., Thompson JC. Preoperative endoscopic retrograde cholangiopancreatography (ERCP) in patients with pancreatic pseudocyst associated with resolving acute and chronic pancreatitis. *Ann Surg* 1989;209:532-8.
 43. Vidyarthi G, Steinberg SE. Endoscopic management of pancreatic pseudocysts. *Surg Clin North Am* 2001;81:405-10, xii.
 44. Barthelet M, Sahel J, Bodiou-Bertelet C, Bernard JP. Endoscopic transpapillary drainage of pancreatic pseudocysts. *Gastrointest Endosc* 1995;42:208-13.
 45. Sanchez CE, Maalak A, Le Moine O, et al. Endoscopic cystenterostomy of nonbulging pancreatic fluid collections. *Gastrointest Endosc* 2002;56:380-6.
 46. Giovannini M, Pesenti C, Rolland AL, Moutardier V, Delperro JR. Endoscopic ultrasound-guided drainage of pancreatic pseudocysts or pancreatic abscesses using a therapeutic echo endoscope. *Endoscopy* 2001;33:473-7.
 47. Baron TH. Endoscopic drainage of pancreatic fluid collections and pancreatic necrosis. *Gastrointest Endosc Clin N Am* 2003;13:743-64.
 48. Gerolami R, Giovannini M, Laugier R. Endoscopic drainage of pancreatic pseudocysts guided by endosonography. *Endoscopy* 1997;29:106-8.
 49. Giovannini M, Binmoeller K, Seifert H. Endoscopic ultrasound-guided cystogastrostomy. *Endoscopy* 2003;35:239-45.
 50. Sriram PV, Kaffes AJ, Rao GV, Reddy DN. Endoscopic ultrasound-guided drainage of pancreatic pseudocysts complicated by portal hypertension or by intervening vessels. *Endoscopy* 2005; 37:231-5.
 51. Chak A. Endosonographic-guided therapy of pancreatic pseudocysts. *Gastrointest Endosc* 2000; 52:S23-S27.
 52. Howell DA, Elton E, Parsons WG. Endoscopic management of pseudocysts of the pancreas. *Gastrointest Endosc Clin N Am* 1998;8:143-62.
 53. Norton ID, Clain JE, Wiersema MJ, DiMaggio EP, Petersen BT, Gostout CJ. Utility of endoscopic ultrasonography in endoscopic drainage of pancreatic pseudocysts in selected patients. *Mayo Clin Proc* 2001;76:794-8.
 54. Monkemuller KE, Baron TH, Morgan DE. Transmural drainage of pancreatic fluid collections without electrocautery using the Seldinger technique. *Gastrointest Endosc* 1998;48:195-200.
 55. Cahen D, Rauws E, Fockens P, Weverling G, Huibregtse K, Bruno M. Endoscopic drainage of pancreatic pseudocysts: long-term outcome and procedural factors associated with safe and successful treatment. *Endoscopy* 2005;37:977-83.
 56. De Palma GD, Galloro G, Puziello A, Masone S, Persico G. Endoscopic drainage of pancreatic pseudocysts: a long-term follow-up study of 49 patients. *Hepatogastroenterology* 2002;49:1113-5.
 57. Hariri M, Slivka A, Carr-Locke DL, Banks PA. Pseudocyst drainage predisposes to infection when pancreatic necrosis is unrecognized. *Am J Gastroenterol* 1994;89:1781-4.
 58. Clark LA, Pappas TN. Long term outcome of endoscopic drainage of pancreatic pseudocysts. *Am J Gastroenterol*

- 1999;94:8-9.
59. Fuchs M, Reimann FM, Gaebel C, Ludwig D, Stange EF. Treatment of infected pancreatic pseudocysts by endoscopic ultrasonography-guided cystogastrostomy. *Endoscopy* 2000;32:654-7.
60. Seifert H, Faust D, Schmitt T, Dietrich C, Caspary W, Wehrmann T. Transmural drainage of cystic peripancreatic lesions with a new large-channel echo endoscope. *Endoscopy* 2001;33:1022-6.
61. Park JJ, Kim SS, Koo YS, et al. Definitive treatment of pancreatic abscess by endoscopic transmural drainage. *Gastrointest Endosc* 2002;55:56-62.