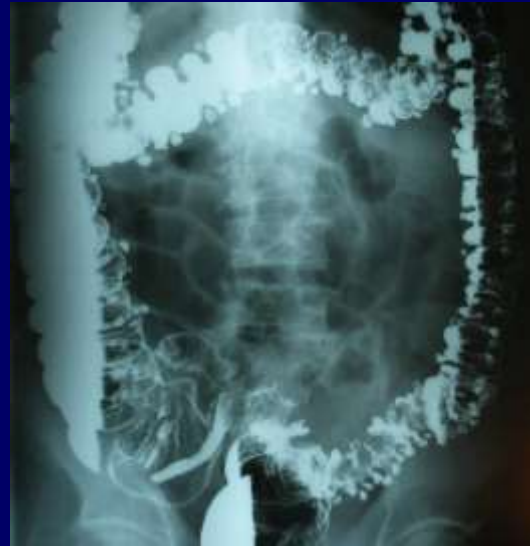



LAPAROSCOPIC COLON RESECTION FOR MANAGEMENT OF COMPLICATED DIVERTICUTIS

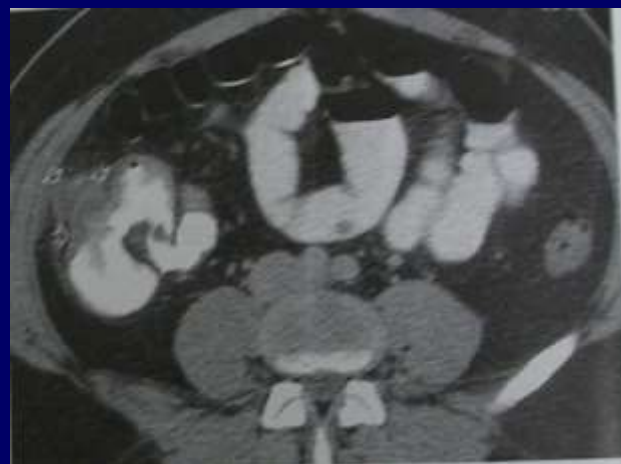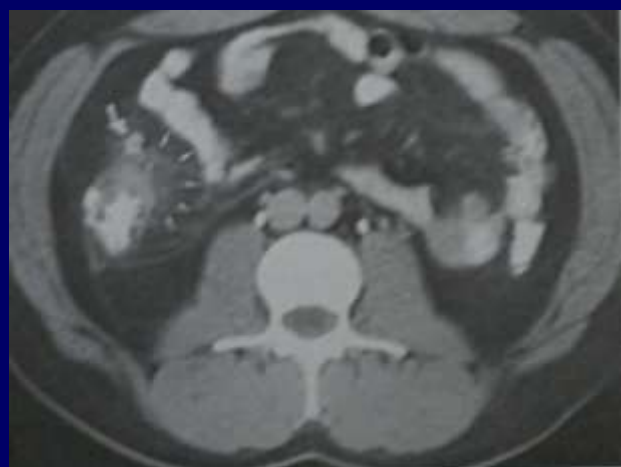
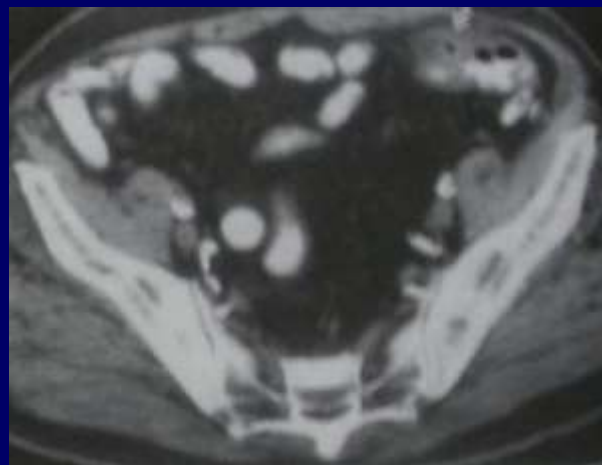
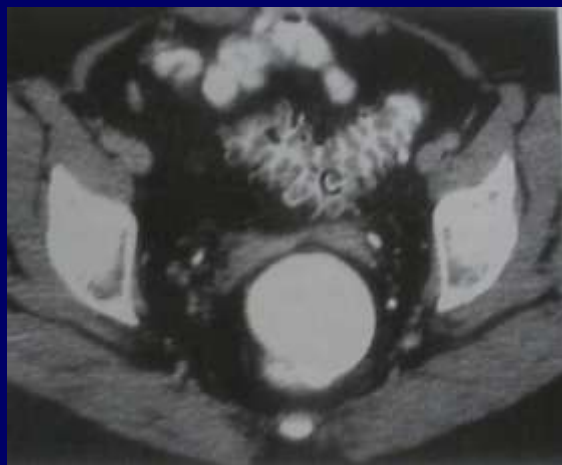Poschong Suesat M.D.

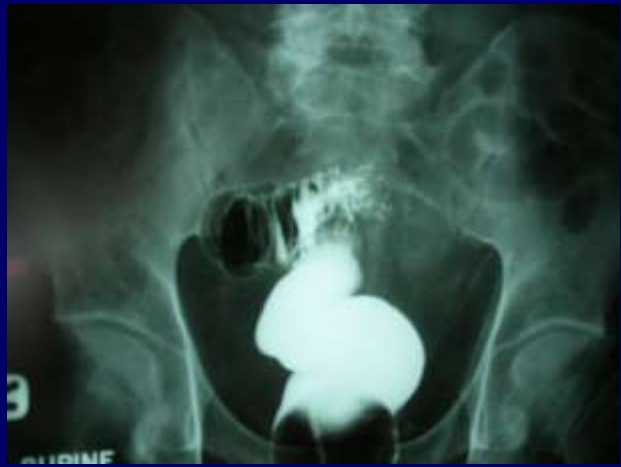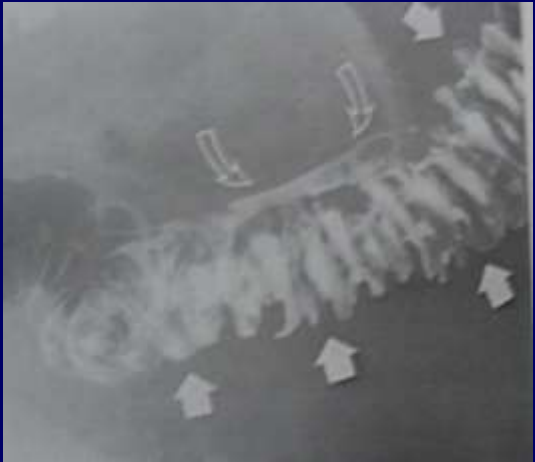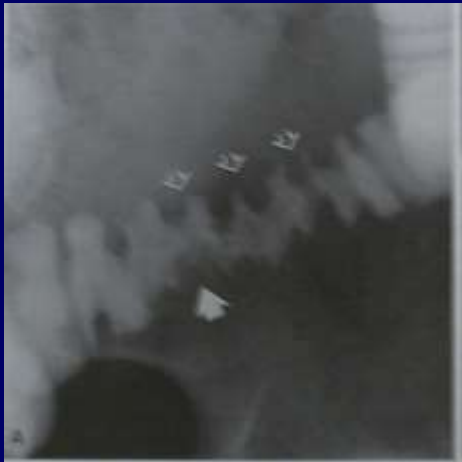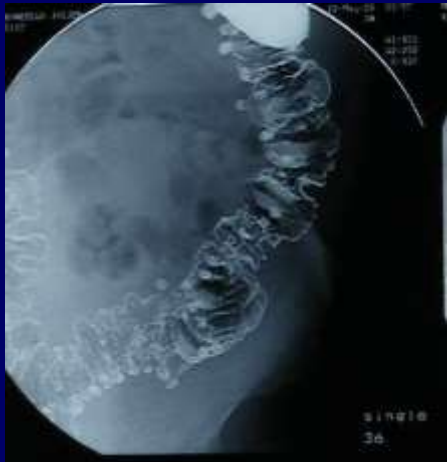
Surgery is seldom indicated in uncomplicated diverticulitis because 70 percent of patients who have recovered from one uncomplicated episode of diverticulitis will have no recurrence.

Complications for diverticular disease and their associated mortality rates are so severe that attempts have been made to define groups of patients who should benefit from elective colon resection to resolve the complications

Indication for Surgery

- Recurrent attacks of local inflammation (two or more)
- Persistent tender abdominal mass
- Narrowing or marked deformity of the sigmoid on radiographic examination
- Dysuria
- Rapid progression of symptoms from time of onset
- Clinical or radiographic signs that do not definitely exclude carcinoma
- Relative young age





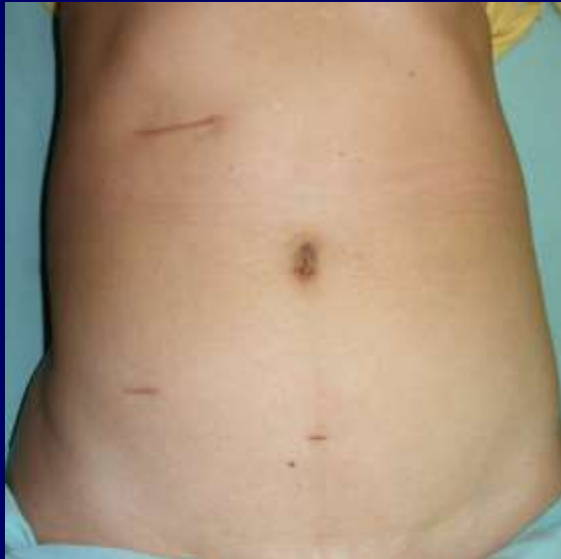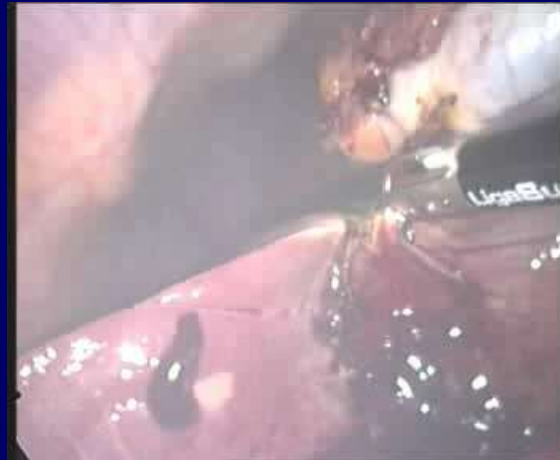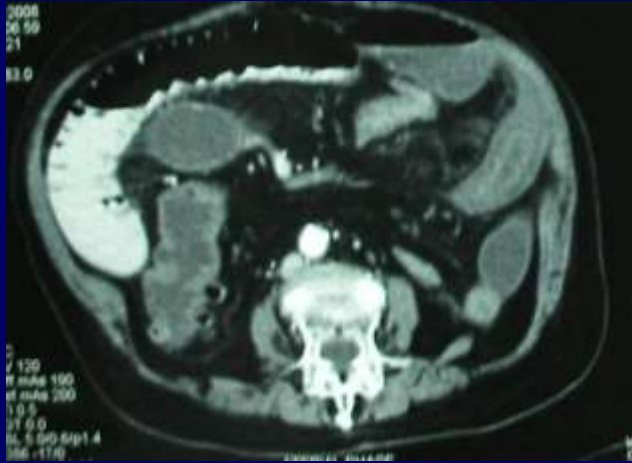Clinical experiences from 1995-2007

	Sex	Age (Years)	Diagnosis	Operation	Operative time (Minutes)	Hospital Stay (Days)
1	Male	69	Diverticulitis of right colon and gallstones	LC and right colectomy	215	5
2	Female	45	Cecal diverticulitis (phlegmon)	Right colectomy	130	4
3	Female	50	Diverticulitis of right colon	Hand-assisted right colectomy	160	7
4	Female	46	Cecal diverticulitis (phlegmon)	Hand-assisted right colectomy	140	7
5	Male	63	Diverticulitis of left colon	Hand-assisted left colectomy	110	7

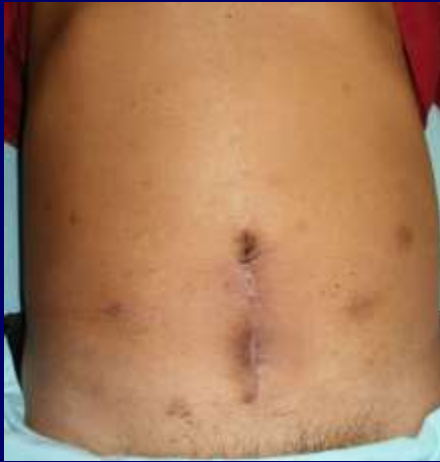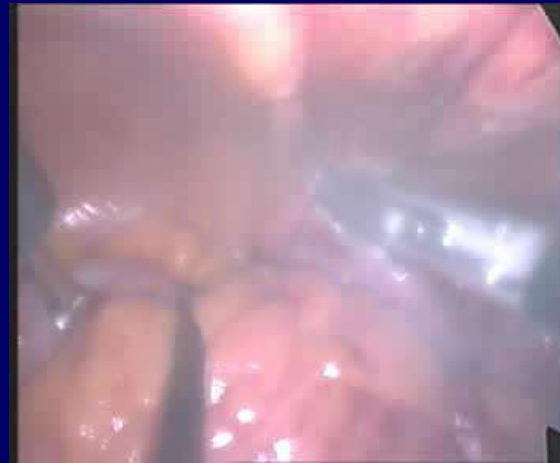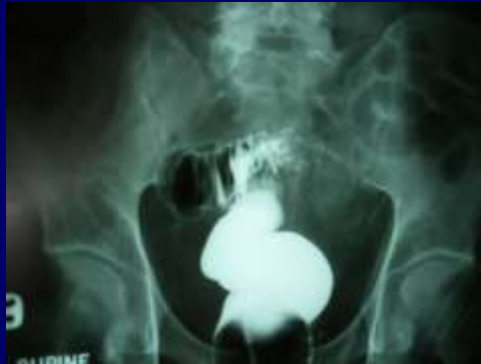	Sex	Age (Years)	Diagnosis	Operation	Operative time (Minutes)	Hospital Stay (Days)
6	Male	48	Sigmoid diverticulitis	Sigmoid colectomy	250	5
7	Male	54	Obstructive sigmoid diverticulitis (phlegmon)	Hand-assisted sigmoid colectomy	230	7
8	Female	54	Extensive diverticulosis with diverticulitis	Hand-assisted subtotal colectomy	190	9
9	Male	79	Extensive diverticulosis with massive hemorrhage	Hand-assisted subtotal colectomy	240	7

Five men and four women 45 - 79 years
Operative times 110-250 minutes
Post operative hospital stay 4 - 9 days

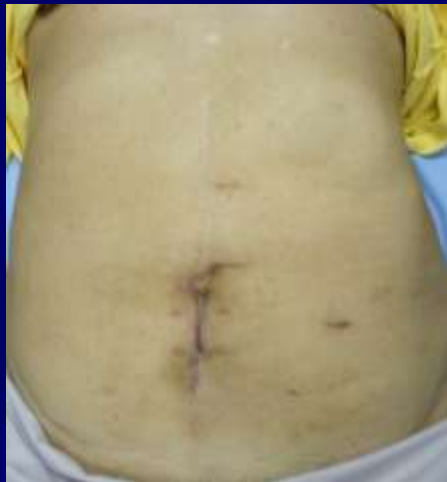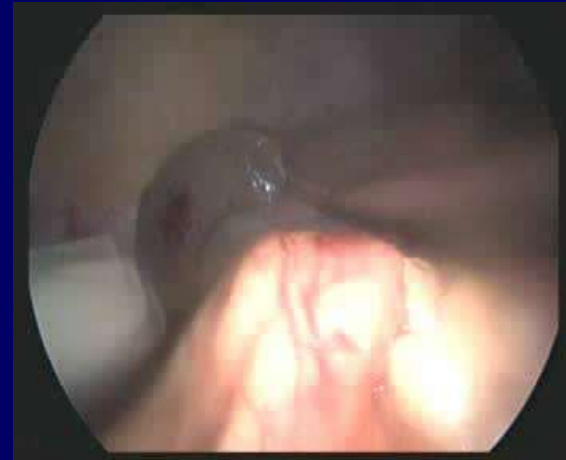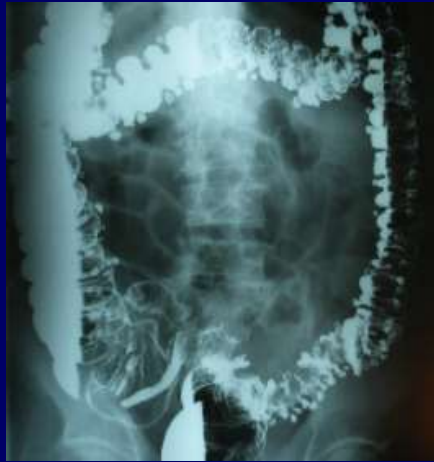Laparoscopic right colectomy



Laparoscopic sigmoid colectomy



Laparoscopic subtotal colectomy



Thank You

for attention