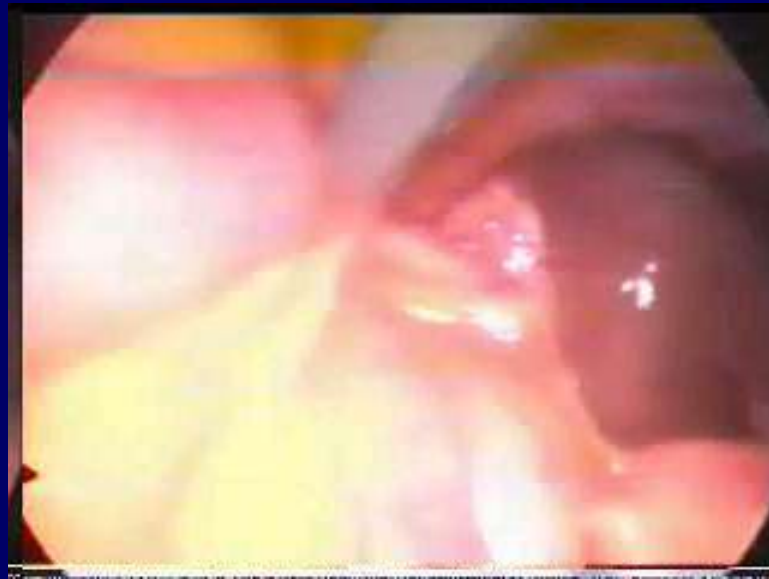



# Laparoscopic Biliary Bypass For Distal Common Bile Duct Obstructions

**Poschong Suesat , MD**

# Bypass of The Extrahepatic Biliary Tract

Benign

Multiple Stones

Intrahepatic Stones

Biliary Tree Packed with Stones

Stenosis of The Papilla of Vater

Malignant

Unresectable Tumor

# The Surgical Biliary Bypass Procedures

Choledochooduodenostomy

Choledochojejunostomy

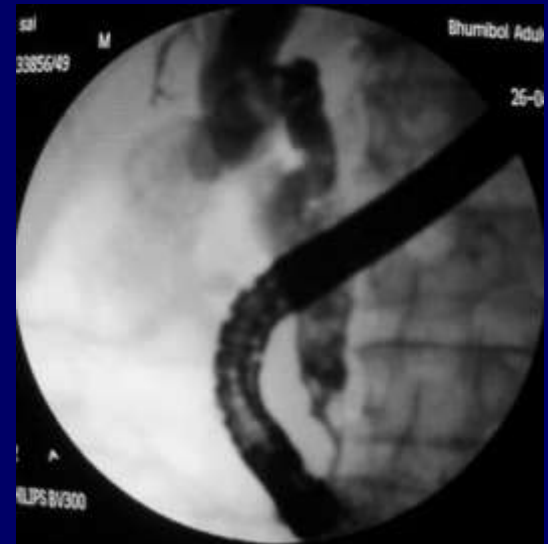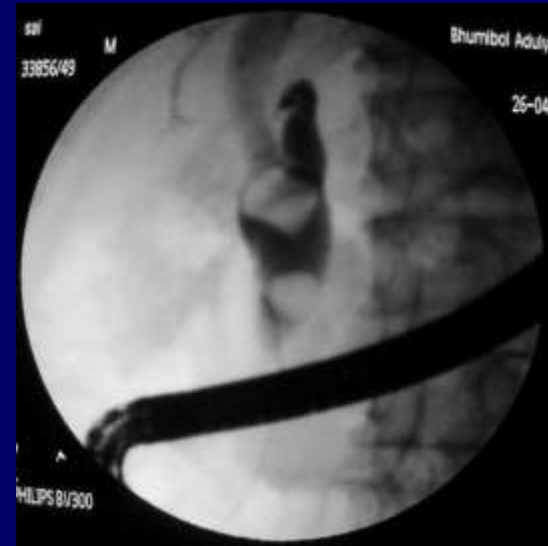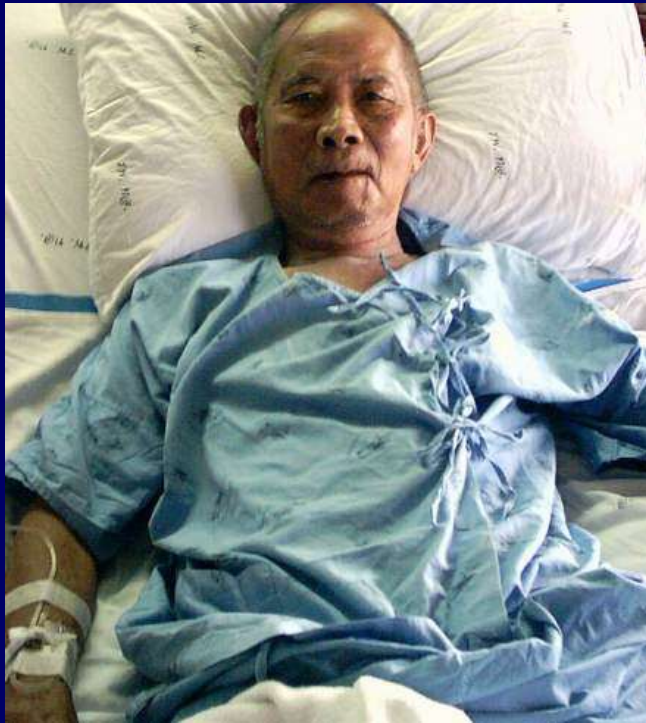Sphincteroplasty

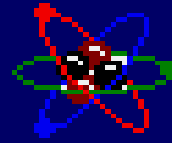
Cholecystojejunostomy

Hepaticodochojejunostomy

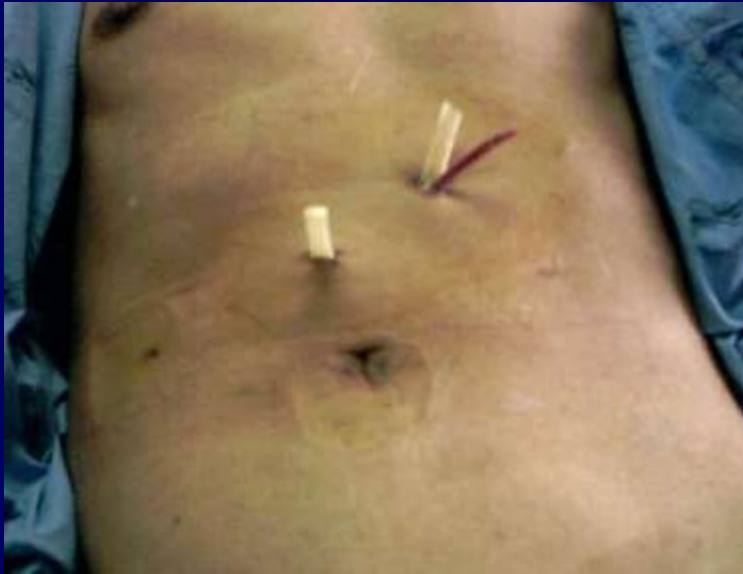
# Case Report No 1

## Laparoscopic Choledochoduodenostomy



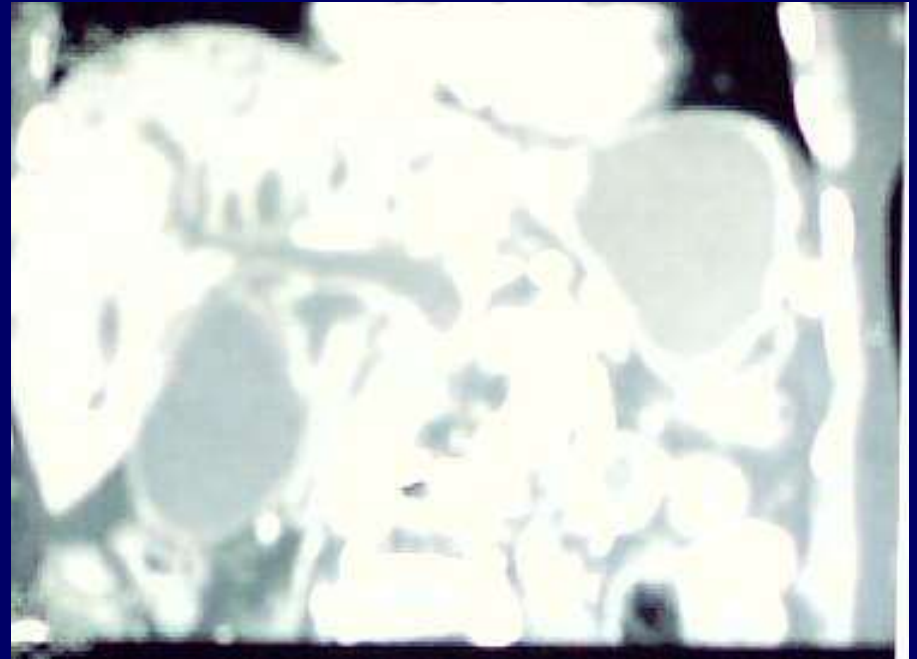
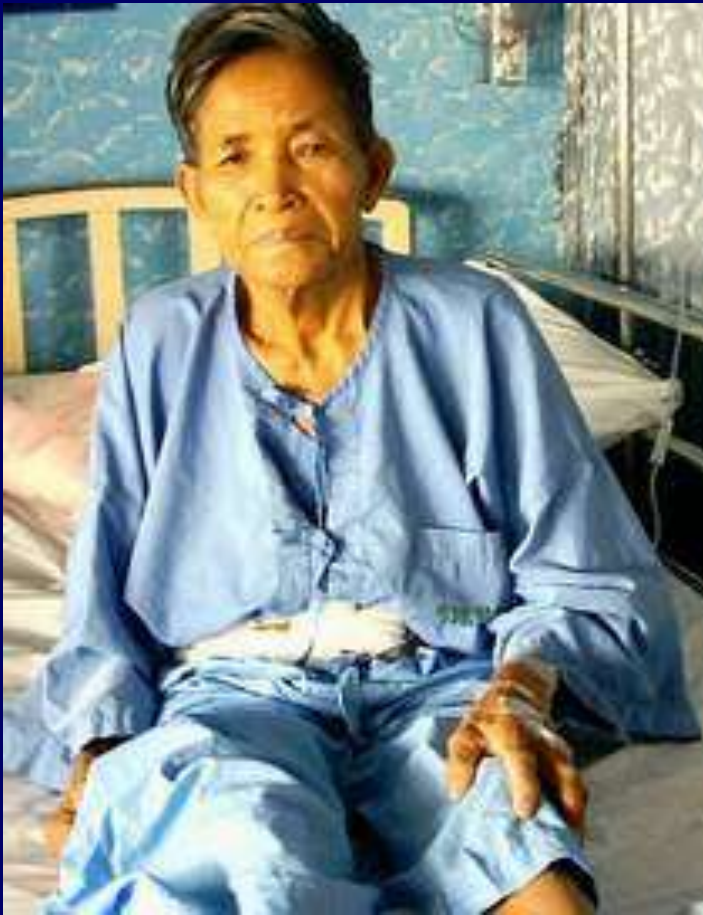

# Laparoscopic Choledochoduodenostomy



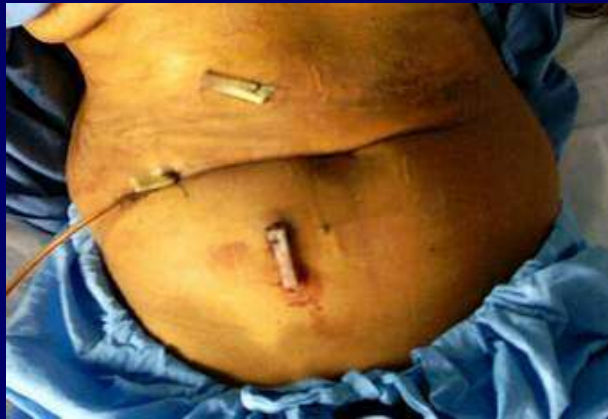
## Case Report No 2

# Laparoscopic Cholecystojejunostomy



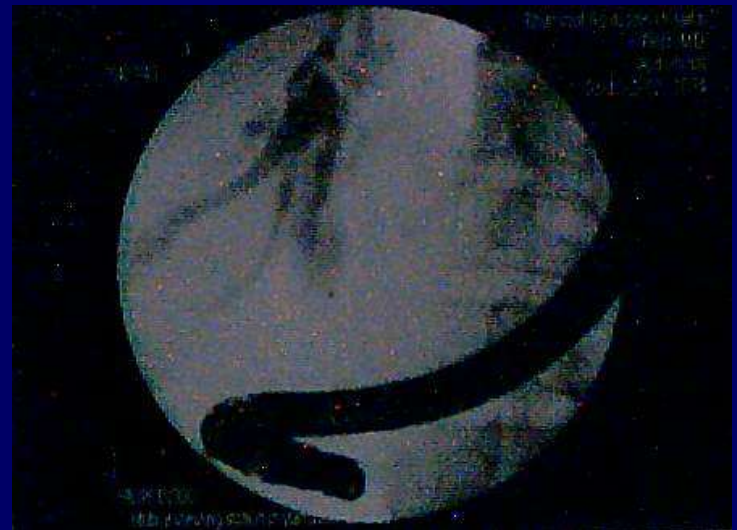
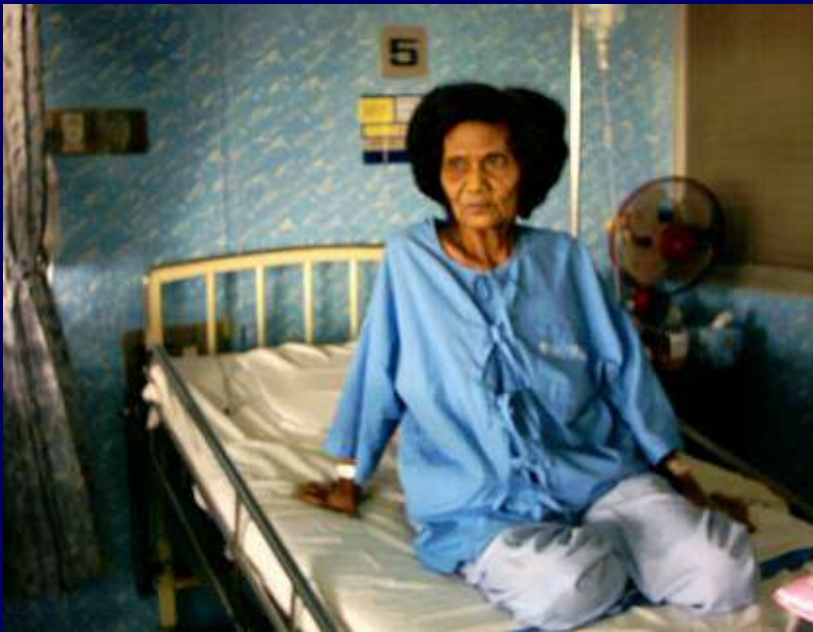
# Laparoscopic Cholecystojejunostomy

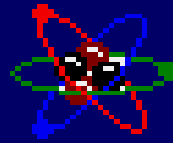


# Case Report No 3

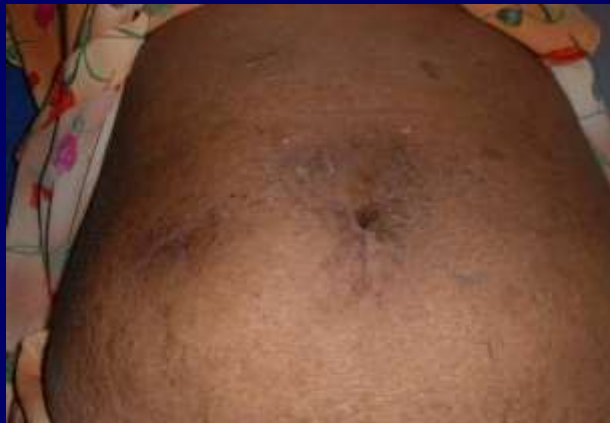
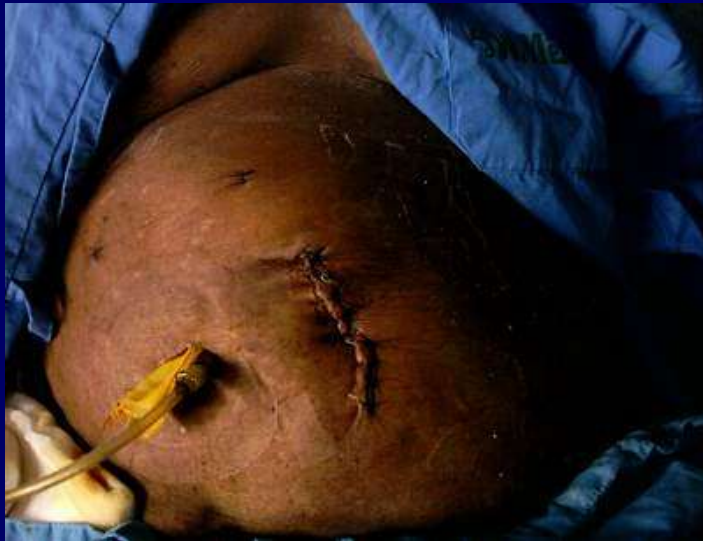## Hand Assisted Laparoscopic Hepaticoduchojejunostomy







# Hand Assisted Laparoscopic Hepaticoduchojejunostomy





**THE  
END**



[www.geocities.com/thaisurgery](http://www.geocities.com/thaisurgery)