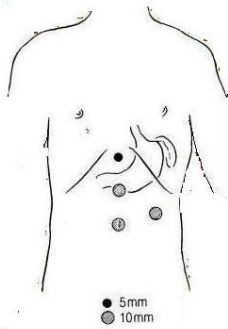
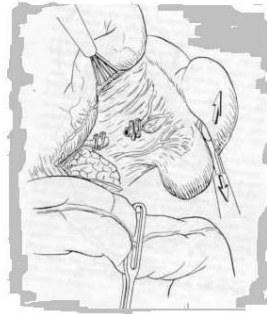

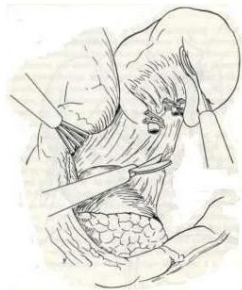Laparoscopic Splenectomy



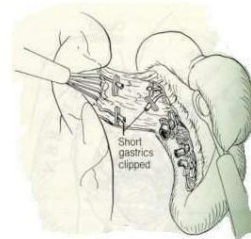
Trocar sites



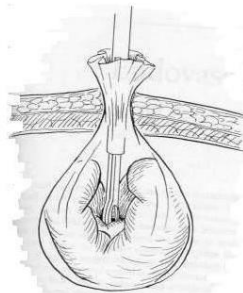
Transection of splenic vessels



Splenorenal ligament transection



Division of short gastric vessels



Splenic removal in the bag

REFERENCE

Minimally Invasive Surgery: John G. Hunter & Jonathan M. Sackier